

Combination of Rectus Sheath Block and Subcostal Transversus Abdominis Plane Block as the Sole Anesthesia for an Open Gastrotomy in a High-risk Patient

Aumjit Wittayapairoj, M.D., Jedniphat Intrapongpan, M.D., Saran Thanharak, M.D.

Department of Anesthesiology, Faculty of Medicine, Khon Kaen University, Khon Kaen 40002, Thailand.

Received 7 June 2023 • Revised 10 July 2023 • Accepted 12 July 2023 • Published online 10 October 2023

Abstract:

Truncal blocks are widely used for postoperative analgesia, but are rarely used for surgical anesthesia. Herein is reported the success of an open gastrotomy under truncal blocks in a patient for whom general anesthesia and neuraxial blockade were undesirable. A 79-year-old man, with advanced esophageal cancer presented with several comorbidities; including cardiomyopathy, ischemic heart disease, and prior cerebral infarction. Difficulty in airway management was anticipated due to the mass's compression on the airway. Anesthesia was achieved using a combination of truncal blocks; this being the rectus sheath block and the subcostal transversus abdominis plane block, supplemented by intravenous fentanyl for managing visceral pain.

Keywords: open gastrotomy, rectus sheath block, regional anesthesia, transversus abdominis plane block, truncal block

Contact: Aumjit Wittayapairoj, M.D.
Department of Anesthesiology, Faculty of Medicine, Khon Kaen University,
Khon Kaen 40002, Thailand.
E-mail: aumjit@kku.ac.th

J Health Sci Med Res
doi: 10.31584/jhsmr.2023999
www.jhsmr.org

© 2023 JHSMR. Hosted by Prince of Songkla University. All rights reserved.
This is an open access article under the CC BY-NC-ND license
(<http://www.jhsmr.org/index.php/jhsmr/about/editorialPolicies#openAccessPolicy>).

Introduction

Anesthesia management in patients with multiple comorbidities is challenging; especially when difficulty in airway management is anticipated. In general, the patient's condition and surgical invasiveness determine the anesthetic technique. For an open gastrostomy, a vertical midline and a small transverse incision in the left part of the upper abdomen are created¹. Although visceral pain may occur from peritoneum and stomach wall manipulation, the pain during this procedure is mainly from the somatic component². Nowadays, with the introduction of portable ultrasound (US) machines in the operating theater, peripheral nerve block techniques have been increasingly utilized. The truncal blocks, e.g., the thoracic paravertebral block (TPVB), transversus abdominis plane block (TAPB), rectus sheath block (RSB), and erector spinae plane block (ESPB), are effective methods for postoperative pain control after abdominal procedures³. However, the role of surgical anesthetic techniques has rarely been discussed. Herein is reported a successful open gastrostomy, under a combination of RSB and subcostal (s) TAPB, in a patient with multiple, serious comorbidities.

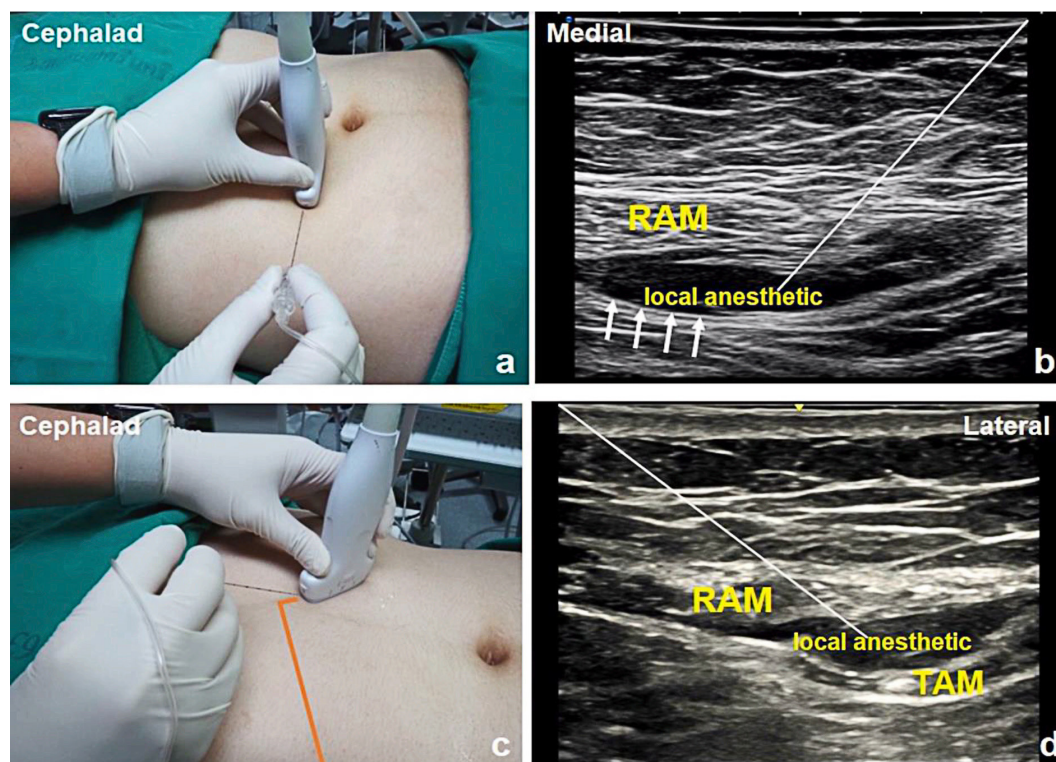
Case report

The patient provided informed consent for this publication, and the Institutional Ethics Committee approved this report (HE651136). A 79-year-old male (170 cm, 52 kg, body mass index of 17.9 kg/m²) was admitted to our hospital due to progressive dysphagia, and significant weight loss of 13 kg within a month. He was diagnosed with advanced upper esophagus cancer, and was scheduled for an open gastrostomy to improve his nutritional status. He had hypertension, diabetes mellitus type 2, dilated cardiomyopathy; due to ischemic heart disease, atrial fibrillation, a history of cerebral infarction, and chronic kidney disease stage 3B. His blood sugar level was in the range of 95–180 mg/dL, with HbA1c being 7.0%. His estimated glomerular filtration rate was 52.0%, and all other

blood investigations; including complete blood cell counts, coagulation profiles, and biochemical assays, had normal findings. Electrocardiography showed atrial fibrillation with anterolateral ischemia. An echocardiography report showed moderate tricuspid and moderate mitral valve regurgitation, an ejection fraction of 39.0%, and global hypokinesia on the anterolateral wall. A coronary angiogram showed 40.0% and 70.0% stenosis of the left main and left circumflex coronary arteries, respectively. A chest x-ray showed patchy infiltration in the right lower lung, with suspected aspiration pneumonia. A fiber-optic examination revealed an irregular surface epithelial mass in the upper esophagus and posterior hypopharynx, with 4 mm of rima glottis. Computed tomography scanning showed a mass lesion size of 4.1×6.5 cm in the upper cervical esophagus and hypopharynx. The right internal carotid artery and internal jugular vein were encased by cancer, rendering them inoperable. Because of the large cancer mass, the endoscopy was impeded; thus, a palliative open gastrostomy tube placement was planned for the patient.

Anesthesia plans were discussed prior to surgery. The surgeons requested general anesthesia (GA), as they expected a larger incision and more procedural complexity than a normal case, which may not have been sufficient with local anesthetic infiltration (LAI). Therefore, a combined RSB and sTAPB was suggested as an alternative, because the patient was at high risk for both GA and neuraxial blockade. The surgeons agreed, and the patients permission was obtained after being informed.

In the block area, the patient was in a supine position, and the abdominal wall was disinfected. The RSB and sTAPB were performed with a 22-G, 80-mm needle (B. Braun, Melsungen, Germany) under US-guidance (SONIMAGE HS1, Konica Minolta, Japan). A linear transducer (15–6 MHz), and the mixture in a 1:1 ratio of 0.5% bupivacaine and 2% lidocaine with a total of 30 ml were used in this case.



RAM=rectus abdominis muscle, TAM=transversus abdominis muscle

Figure 1 Ultrasound transducer placement and ultrasound images of the rectus sheath block and the subcostal transversus abdominis plane block showing the needle pathway and local anesthetic deposited

a) transducer placement for performing the rectus sheath block, b) ultrasound image of the rectus sheath block, c) transducer placement for performing the subcostal transversus abdominis plane block, d) ultrasound image of the subcostal transversus abdominis plane block. white line=represents the needle, white arrows=represents the posterior rectus sheath, orange line=represents the costal margin line

To perform the right RSB, the transducer was placed in a transverse position at the right lateral of the midline; just above the umbilicus (Figure 1a). After infiltrating the skin with 1% lidocaine, the block needle was inserted from the lateral to the medial, with an in-plane approach to pierce through the anterior rectus sheath (RS) and rectus abdominis muscle (RAM). The needle was further advanced until the tip was in the plane between the RAM and the posterior RS. After negative aspiration, the mixture of local anesthetic (LA) was incrementally injected up to 10 ml (Figure 1b). For the left sTAPB, the transducer was initially placed in a transverse

view below the xiphoid process. Then it was moved obliquely downward, parallel to the costal margin (Figure 1c), until the transversus abdominis muscle (TAM) came into view below the RAM. Skin infiltration was performed, followed by the insertion of the block needle in an in-plane approach from the medial to the lateral direction. The needle was advanced until it reached the fascia between the RAM and TAM. At this point, LA was incrementally injected to the level of 10 ml (Figure 1d). Then the transducer was moved further downward to identify the transversus abdominis plane (TAP), the plane between the internal oblique muscle

and the TAM. The needle was further advanced to enter this plane, and another 10 ml of LA was slowly injected as the needle was dynamically advancing. A sensory blockade was evaluated 20 minutes after performing the block with the pin-prick test. The loss of sharpness sensation in the midline area from the dermatomal level of thoracic (T) 6 to T10, and on the left side of the anterior abdominal wall was achieved.

In the operating room, the patient received 3 L/min of oxygen via a nasal cannula and was monitored for vital signs. A 10-cm midline incision and a small transverse incision in the left upper abdomen were created (Figure 2). The patient was comfortable throughout the operation without any need for additional LAI by the surgeon. Only intravenous (IV) 50 mcg of fentanyl was administered to manage the visceral pain. The operation took 75 minutes, and then the patient was transferred to the recovery room with a reported pain score of zero. The patient was transferred to the ward without incident an hour later.

Discussion

Truncal blocks have been widely used for postoperative analgesia, with limited use as surgical anesthesia. This report discussed a successful open gastrostomy under a combination of truncal blocks (RSB and sTAPB) in advanced esophageal cancer, with multiple comorbidities and an expected difficult airway.

In general, this surgery can be done under the LAI technique, neuraxial blockade (spinal block or epidural block), or GA^{1,4}. In this case, LAI was not selected, as our surgeons anticipated a wider incision and more difficult surgical techniques than usual, which may not be adequate for the LAI technique. Additionally, a previous study stated that the LAI technique causes a high GA conversion rate due to the limitations of the blockade area⁵. Neuraxial blockade is an effective anesthetic technique for open gastrostomy that can be used safely in most cases. However, severe hemodynamic instability is hard to avoid and less compensated, particularly in a fragile and cachectic

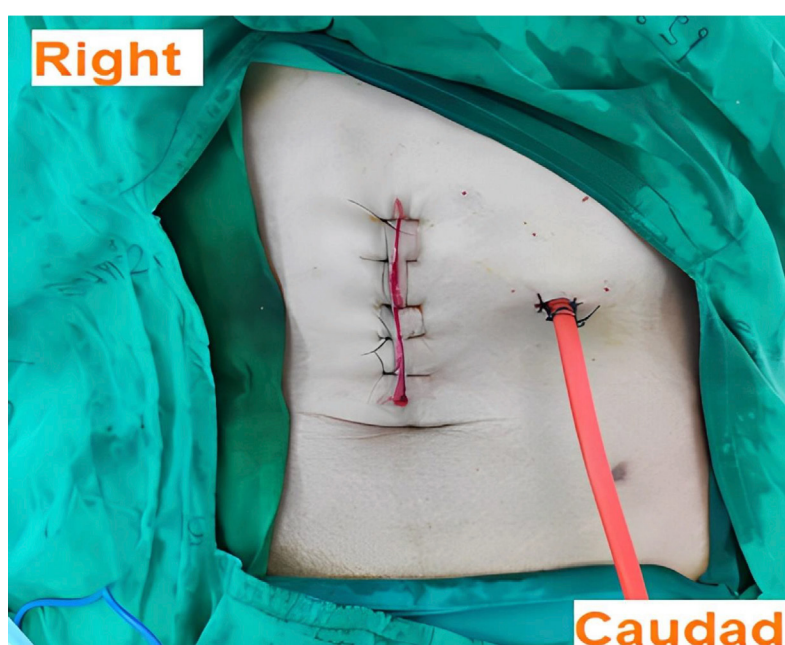


Figure 2 The surgical incision after an open gastrostomy

patient; such as in this patient⁶. Additionally, it was decided against administering GA to this patient; considering endotracheal intubation might be necessary to maintain the airway during the operation. It was highly challenging to manage the patient's airway because a cancer mass had invaded some areas of the upper part of the airway. This may have resulted in a disastrous failure to intubate and oxygenate the patient. Moreover, given that the procedure was not notably invasive, the GA technique could possibly be unnecessary and overdone.

Hence, a combined right RSB and left sTAPB was performed in this case. RSB is a truncal block technique that aims to anesthetize T7–T12 spinal nerves as they enter the lateral aspect of RAM. This technique provides dense and predictable somatic anesthesia to the anterior abdomen, and is suitable for umbilical and peri-umbilical procedures^{7,8}. The TAPB was introduced in 2001 by Dr. Rafi, who used landmarks as the basis for the initial description of the technique. The block aims to anesthetize the anterior branch of the spinal nerves that run in TAP³. Since the US machine was launched, the method has gained favor as it offers safer and more accurate blocks, and many approaches for TAPB have since been developed. In general, the anterior branches of the T10–T12 spinal nerves and the first lumbar spinal nerves are consistently anesthetized via a conventional TAPB (lateral approach)^{3,9}. However, a subcostal approach of TAPB generated a higher level of blocking from T7–T10 dermatomes, which is more appropriate for supra-umbilical abdominal wall surgery^{2,6}.

Bilateral RSB was not selected for this patient due to the specific and constrained area of blockade at the umbilical and peri-umbilical areas used in the technique, which may not cover the gastrotomy tube exit hole; located in the more lateral part of the abdomen^{7,8}. However, bilateral sTAPB may be an alternative because it anesthetizes the entire upper abdominal wall. Nevertheless, this technique typically requires a large amount of LA (20–25 ml per side) to be employed for extensive spreading in TAP. Hence, increasing

the risk of LA toxicity; especially when bilateral sides of the blockade are needed, and particularly in a frail and low-weight patient; such as this patient^{3,6}. In our opinion, right RSB and left sTAPB were a suitable combination for this patient, as they helped overcome somatic pain from both the midline and left part of the abdomen incisions while minimizing LA volume. The combination of RSB and TAPB as the sole anesthesia has also been evident for peritoneal dialysis catheter placement surgery¹⁰. However, a different technique of TAPB was used, which was different from this reported case. In the latter study, the lateral approach of TAPB was selected because sensory blockade from T8–T12 levels was required for this type of procedure.

There have been previous reports describing the value of other truncal blocks as a sole anesthetic technique for open gastrotomy in patients with significant comorbidities; such as ESPB and TPVB^{11,12}. The ESPB, a recently developed truncal block, deposited the LA in the plane between the erector spinae muscle and the underneath transverse process. It has become a favorite technique because of its simplicity, lack of technical expertise, and safety; as the target is not in proximity to any vital structures. Additionally, it has the ability to provide a wide area of dermatomal coverage with a single injection method.

However, the technique has been mostly used for postoperative pain control after surgery, as the weak intensity and inconsistency of the blockade have made it problematic to apply for anesthesia purposes¹³. The TPVB, on the other hand, is reliable and produces an intense sensory blockade, as it directly deposits the LA in the space where the proximal spinal nerves are located; thus, it has shown benefits for surgical anesthesia purposes^{14,15}. However, the technical challenges, as it is a deep block, make it not a technique of choice for inexperienced performers and patients with coagulopathy¹³. In addition, hypotension due to potential epidural spreading and sympathetic blockades may also preclude the application of this block in critical or vulnerable cases³. Like most truncal

blocks, neither RSB nor TAPB cover visceral pain. Thus, additional systemic analgesia; such as intravenous opioids or non-narcotic analgesics, is required to manage pain during visceral manipulation^{6,7,9}. In this case, a small dose of IV fentanyl (50 mcg) was administered, which provided for a smooth procedure.

Conclusion

The value of using RSB and sTAPB in combination as the sole anesthetic technique for non-invasive supra-umbilical abdominal surgeries; such as open gastrostomy, is highlighted in this article. When GA or neuraxial blockade is unfavorable for a patient and the procedure cannot be performed under LAI, these truncal blocks may be a worthwhile alternative.

Funding sources

None

Conflict of interest

Nothing to declare.

References

1. Faria GR, Taveira-Gomes A. Open gastrostomy by mini-laparotomy: A comparative study. *Int J Surg* 2011;9:263–6.
2. Lee AR, Choe YS. Anesthesia experience for open gastrostomy with ultrasound-guided unilateral subcostal transversus abdominis plane block in a high risk elderly patient: a case report. *Anesth Pain Med* 2015;5:e24890.
3. Chakraborty A, Khemka R, Datta T. Ultrasound-guided truncal blocks: A new frontier in regional anaesthesia. *Indian J Anaesth* 2016;60:703–11.
4. Ruiz-Chirosa MDC, Nieto-Martín L, García-Fernández E, Vaquero-Roncero LM, Sánchez-Montero JM, Alonso-Guardo L, et al. Epidural anesthesia for open gastrostomy in a patient with amyotrophic lateral sclerosis. *Rev Colomb Anestesiol* 2018;46:246–9.
5. Li Q, Tang X, Tao T, Zhang W, Qin W, Zhang J, et al. A randomized controlled trial of comparing ultrasound-guided

- transversus abdominis plane block with local anesthetic infiltration in peritoneal dialysis catheter implantation. *Blood Purif* 2018;45:8–14.
6. Soliz JM, Lipski I, Hancher-Hodges S, Speer BB, Popat K. Subcostal transverse abdominis plane block for acute pain management: a review. *Anesth Pain Med* 2017;7:e12923.
7. Kartalov A, Jankulovski N, Kuzmanovska B, Zdravkovska M, Shosholcheva M, Tolevska M, et al. The effect of rectus sheath block as a supplement of general anesthesia on postoperative analgesia in adult patient undergoing umbilical hernia repair. *Prilozi* 2017;38:135–42.
8. Quek KHY, Phua DSK. Bilateral rectus sheath block as the single anaesthetic technique for an open infraumbilical hernia repair. *Singapore Med J* 2014;55:39–41.
9. Lissauer J, Mancuso K, Merritt C, Prabhakar A, Kaye AD, Urman RD. Evolution of the transversus abdominis plane block and its role in postoperative analgesia. *Best Pract Res Clin Anaesthesiol* 2014;28:117–26.
10. Li J, Guo W, Zhao W, Wang X, Hu W, Zhou J, et al. Ultrasound-guided unilateral transversus abdominis plane combined with rectus sheath block versus subarachnoid anesthesia in patients undergoing peritoneal dialysis catheter surgery: a randomized prospective controlled trial. *J Pain Res* 2020;13:2279–87.
11. Kalava A, Chambers TJ, Hoffman JF. Bilateral thoracic paravertebral nerve blocks for open gastrostomy in patients with amyotrophic lateral sclerosis. *Cureus* 2020;12:10–2.
12. Bagaphou CT, Piraccini E, Norgiolini L, Ciabucchi C, Carsena V, et al. Anesthesia experience for open gastrostomy with ultrasound-guided erector spinae plane block: a case report. *Case Rep Anesthesiol* 2020;2020:5413848.
13. Wittayapairoj A, Sinthuchao N, Somintara O, Thincheelong V, Somdee W. A randomized double-blind controlled study comparing erector spinae plane block and thoracic paravertebral block for postoperative analgesia after breast surgery. *Anesth Pain Med* 2022;17:445–53.
14. Simpson J, Ariyaratnam A, Dunn J, Ford P. Breast surgery using thoracic paravertebral blockade and sedation alone. *Anesthesiol Res Pract* 2014;2014:127467.
15. Bejrananda T, Pakpirom J. Successful percutaneous nephrolithotomy using thoracic paravertebral block as the sole surgical anesthesia: cases report. *J Health Sci Med Res* 2021; 39:423–9.