

# Epidermolytic Ichthyosis Sine Epidermolysis—A Case Report and Molecular Analysis

Phanitchanat Phusuphitchayanan, M.D., Apasee Sooksamran, M.D.,  
Chavalit Supsrirunjai, M.D., Ph.D.

Institute of Dermatology, Department of Medical Services, Ministry of Public Health, Phayathai, Bangkok 10400, Thailand.

Received 14 May 2022 • Revised 22 July 2022 • Accepted 3 October 2022 • Published online 21 November 2022

### Abstract:

Epidermolytic ichthyosis (EI) is a rare genodermatosis disorder. We report a 39-year-old woman with EI, who presented with generalized erythroderma since birth, followed by generalized hyperkeratosis later in life. The physical examination revealed generalized hyperkeratosis without blistering or erosion. The histopathological studies revealed hyperkeratosis with parakeratosis and psoriasiform hyperplasia, without significant epidermolysis. The Sanger sequencing revealed a missense mutation—c.467G>A (p.Arg156His)—in the *KRT10* gene, confirming the diagnosis of EI. The genotype–phenotype correlations in EI patients are multifactorial. Thus, molecular analysis can confirm the diagnosis in cases of an unclear medical history or histological inconclusiveness.

**Keywords:** bullous congenital ichthyosiform erythroderma, epidermolytic hyperkeratosis, epidermolytic ichthyosis, *KRT10*, p.Arg156His

**Contact:** Chavalit Supsrirunjai, M.D., Ph.D.  
Institute of Dermatology, Department of Medical Services, Ministry of Public Health,  
Phayathai, Bangkok 10400, Thailand.  
E-mail: chervilius@hotmail.com

J Health Sci Med Res .....  
doi: 10.31584/jhsmr.2022914  
www.jhsmr.org

© 2022 JHSMR. Hosted by Prince of Songkla University. All rights reserved.  
This is an open access article under the CC BY–NC–ND license  
(<http://www.jhsmr.org/index.php/jhsmr/about/editorialPolicies#openAccessPolicy>).

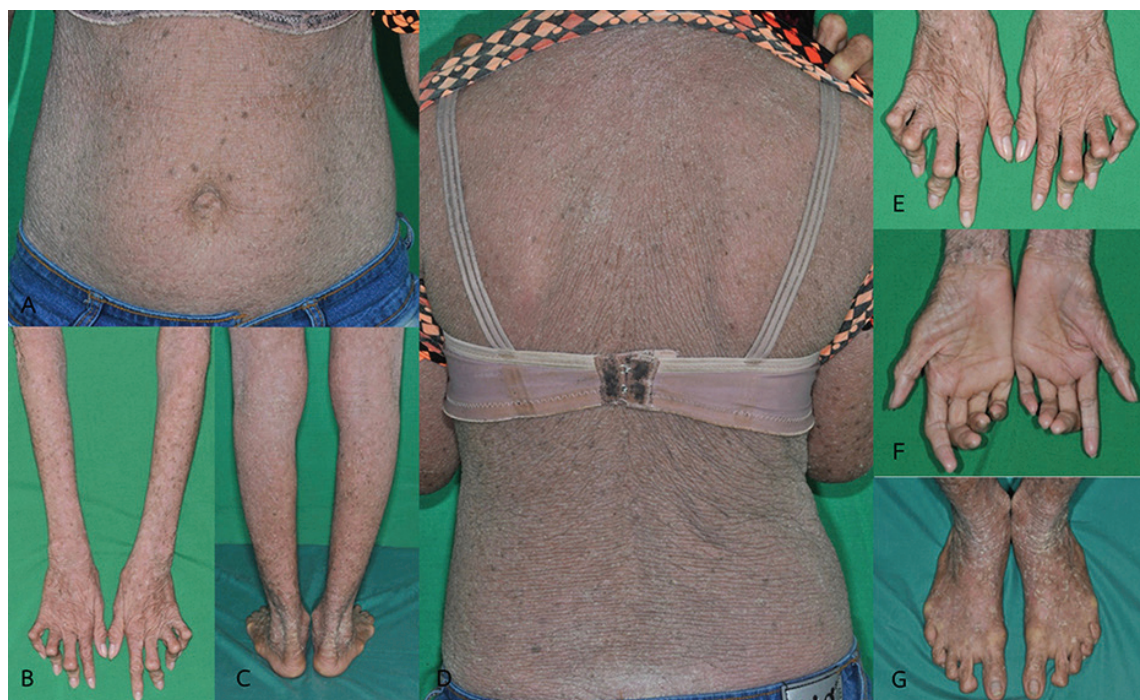## Introduction

Epidermolytic ichthyosis (EI), formerly known as bullous congenital ichthyosiform erythroderma of Brocq, is a rare type of genodermatosis that affects approximately 1 in 200,000–300,000 people worldwide.<sup>1</sup> The disease is characterized by congenital ichthyosiform erythroderma at birth, which is frequently accompanied by blistering, peeling, or erosion. Later during infancy, it is also followed by hyperkeratosis and thickened skin, especially around the joints. Its pathogenesis is widely known and is caused by heterozygous mutations in the genes *KRT1* and *KRT10*, which encode keratin 1 and 10, respectively, and are inherited in an autosomal dominant manner with complete penetrance. Sporadic mutations, which occur in 50% of these genes, have been associated with the development of EI-patterned cutaneous mosaicism on the lines of Blaschko.<sup>2</sup> The characteristic histologic features are epidermolysis of the suprabasal and granular layers and

epidermolytic hyperkeratosis (EHK). We present a case of generalized hyperkeratosis in a woman clinically and molecularly diagnosed with EI.

## Case Report

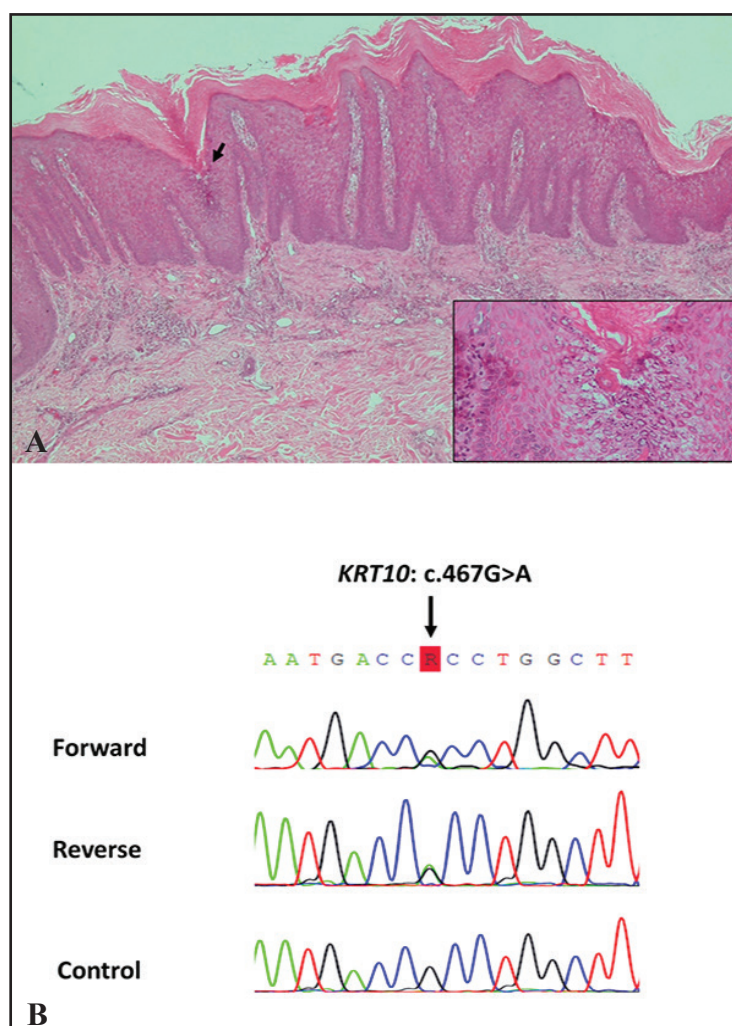
A 39-year-old woman presented with generalized erythroderma and desquamation since birth. Later in life, she developed generalized marked hyperkeratosis without palmoplantar keratoderma. The patient and her parents had no history of skin blistering at birth. The affected skin was thick and darkened, and accentuated creases had formed over time. She was unable to fully extend her fingers and toes. To her knowledge, she had no family history of similar skin conditions. Physical examination revealed generalized scaly hyperkeratotic plaques over the face, trunk, and extremities, with skin crease accentuation over the joints and body folds. There were no blisters, erosion, or ectropion/eclabium on the periorificial skin.



**Figure 1** Epidermolytic ichthyosis. (A–D) Widespread scaly brownish hyperkeratosis and multiple lentigines are noted. (E–G) Contraction deformity affected fingers and toes.

Notably, multiple lentigines and pigmented lesions were observed in both sun-exposed and sun-protected areas. Flexion deformity affected the third to fifth fingers of both hands and the second to fifth toes of both feet (Figure 1). Histopathological examination of a skin biopsy specimen revealed hyperkeratosis with parakeratosis, psoriasiform hyperplasia, mild papillomatosis, and superficial perivascular

lymphocytic infiltration; acantholysis or epidermolysis was not observed (Figure 2A). After obtaining informed consent, Sanger sequencing was performed, and a missense mutation, c.467G>A (p.Arg156His), in *KRT10* was detected (Figure 2B), leading to the diagnosis of EI. The patient received 25 mg of oral acitretin daily, which improved skin thickening but not the contracture.



**Figure 2** (A) Confluent orthokeratosis, regular acanthosis, and superficial perivascular lymphocytic infiltration. The area of intracytoplasmic vacuolization of keratinocytes is not clearly seen. Irregular and enlarged clumping of eosinophilic intracytoplasmic inclusions are noted (black arrow and insert). (B) Gene sequencing demonstrates a heterozygous missense mutation c.467G>A (black arrow) in exon 1 of *KRT10*, resulting in substitution with a histidine residue (p.Arg156His).

## Discussion

Our report describes an unusual case of EI without a history of skin blistering. EI is an autosomal dominant inherited ichthyosis caused by mutations in the suprabasal keratin 1 and 10 genes.<sup>3</sup> These keratins are co-expressed in the differentiated spinous and granular layers of stratified epithelia. *KRT1* is abundant in palmar and plantar skin, but *KRT10* is expressed less in these regions. Different expression sites of keratin 1 and keratin 10 result in some distinct clinical differences.<sup>1</sup> Their functions are to maintain cellular integrity and provide mechanical strength to the epidermis. The mutations in *KRT1* and *KRT10* in EI result in the clumping of mutant keratin intermediate filaments leading to the collapse of the cell skeleton network and, eventually, the cytolysis of keratinocytes.<sup>1</sup> Consequently, clinically severe blistering of the skin develops.<sup>3</sup> Additionally, keratins 1 and 10 play a role in cell proliferation; thus, a deficiency in these keratins results in the development of hyperkeratosis.<sup>4</sup> Moreover, their aggregation and clumping are cytotoxic to keratinocytes, and they have been shown to disrupt cell differentiation and the formation of the lipid permeability barrier of the epidermis. Therefore, a disturbance of the barrier function occurs, leading to an increased transepidermal water loss and bacterial colonization.

The histopathological symptoms of EHK are as follows: (1) keratin tonofilament perinuclear shell aggregation within suprabasal keratinocytes, (2) hyperkeratosis of the stratum corneum with focal parakeratosis, (3) hyperproliferation of basal keratinocytes, and (4) suprabasal keratinocyte degeneration.<sup>2,3</sup> The histopathological examination in our case revealed no characteristic evidence of EI. Clinically and histologically, ichthyosis hystrix Curth–Macklin, non-bullous congenital ichthyosiform erythroderma, and other congenital ichthyoses were potential diagnoses.

To further confirm the diagnosis, we performed direct gene sequencing, which revealed a mutation in *KRT10*

(Figure 2B). This mutation resulted in the substitution of conserved arginine with a histidine residue at position 156 of keratin 10 (p.Arg156His). Notably, the arginine at position 156 of *KRT10*, which is located in the conserved region of the rod domain, is structurally important for filament assembly; thus, mutation at this point results in a severe phenotype. Mutations in other amino acids, which do not lie within highly conserved residues, show a less severe effect on the intermediate filament.<sup>7</sup> Generally, mutations in *KRT1* and *KRT10* cause different phenotypes; for example, severe palmoplantar keratoderma occurs from a mutation in *KRT1*, but not in *KRT10*. However, differences in histological features have not been described.<sup>1</sup> Eskin–Schwartz et al. reported a four-generation Russian family with localized symmetric hyperkeratotic lesions without blistering or skin fragility in individuals affected by a *KRT10* mutation (c.1322G>C/WT); the disease was diagnosed as EI sine epidermolysis.<sup>5</sup> Similar to our case, histological findings of the affected offspring showed small foci of intercellular separation in the spinous layer without evidence of gross acantholysis, despite the presence of a mutation affecting highly conserved regions of the rod domain.

The p.Arg156His mutation is reportedly common according to previous reports. However, large clinical variations have been observed.<sup>6</sup> Syder et al. explored the correlation between EHK severity and the extent of the associated mutation. They discovered that two severe cases shared the same mutation, which changed a conserved arginine to histidine at the amino acid end of *KRT10*'s alpha-helical rod domain. This variant is associated with EHK severity, as evidenced by histological suprabasal cell degeneration and cytolysis.<sup>7</sup> The same mutation caused the severe hyperkeratotic phenotype in our case; however, our patient had neither blistering nor acantholysis, which may be explained by the highly complex genotype–phenotype correlations in patients with EHK. The actual amino acid substitution is as important as the position of the mutation

in determining the phenotype of the patient.<sup>6,8-10</sup> To our knowledge, EI is inherited autosomally with complete penetration, and spontaneous mutations are also common. The absence of an affected family member suggested that the mutation appeared de novo in our patient.

## Conclusion

We describe a case of EI without overt epidermolysis caused by a point mutation in exon 1 of the *KRT10* gene. Although this genotype has been previously described as leading to severe epidermolysis, our patient demonstrated minimal cell-to-cell separation without overt acantholysis. Therefore, physicians should be careful when clinical signs suggest EI, but there is no obvious epidermolytic change. Molecular diagnosis can be important in confirming cases with an unclear history or inconclusive histologic findings. Early diagnosis and treatment provide favorable outcomes, particularly in cases of contraction deformities.

## References

1. Bologna JL, Schaffer JV, Cerroni L. *Dermatology*. 4<sup>th</sup> ed. Amsterdam: Elsevier; 2018.
2. Ross R, DiGiovanna JJ, Capaldi L, Argenyi Z, Fleckman P, Robinson-Bostom L. Histopathologic characterization of epidermolytic hyperkeratosis: a systematic review of histology from the National Registry for Ichthyosis and Related Skin Disorders. *J Am Acad Dermatol* 2008;59:86–90.
3. Rout DP, Nair A, Gupta A, Kumar P. Epidermolytic hyperkeratosis: clinical update. *Clin Cosmet Investig Dermatol* 2019; 12:333–44.
4. Hayashida MT, Mitsui GL, Reis NI, Fantinato G, Jordão Neto D, Mercante AM. Epidermolytic hyperkeratosis—case report. *An Bras Dermatol* 2015;90:888–91.
5. Eskin-Schwartz M, Drozhkina M, Sarig O, Gat A, Jackman T, Isakov O, et al. Epidermolytic ichthyosis sine epidermolysis. *Am J Dermatopathol* 2017;39:440–4.
6. Li Z, Liu Q, Wang A, Wang H, Li C. Mutation p.R156H of *KRT10* responsible for severe phenotype of epidermolytic ichthyosis in a Chinese family. *Ther Clin Risk Manag* 2014;10:713–5.
7. Syder AJ, Yu QC, Paller AS, Giudice G, Pearson R, Fuchs E. Genetic mutations in the *K1* and *K10* genes of patients with epidermolytic hyperkeratosis. Correlation between location and disease severity. *J Clin Invest* 1994;93:1533–42.
8. Virtanen M, Vahlquist A, Smith SK, Gedde-Dahl Jr T, Bowden PE. Splice site and deletion mutations in keratin (*KRT1* and *KRT10*) genes: unusual phenotypic alterations in Scandinavian patients with epidermolytic hyperkeratosis. *J Invest Dermatol* 2003;121:1013–20.
9. Sun X, Ma L, Xie Y, Zhu X. Keratin 1 and keratin 10 mutations causing epidermolytic hyperkeratosis in Chinese patients. *J Dermatol Sci* 2002;29:195–200.
10. Arin MJ, Oji V, Emmert S, Hausser I, Traupe H, Krieg T, et al. Expanding the keratin mutation database: novel and recurrent mutations and genotype–phenotype correlations in 28 patients with epidermolytic ichthyosis. *Br J Dermatol* 2011;164:442–7.