

Single-stage Total Hip Arthroplasty and Fixation of Acetabulum Fracture in Patients with Osteogenesis Imperfecta

Chulin Chewakidakarn, M.D., Pornpanit Dissaneewate, M.D., Apipop Kritsaneepaiboon, M.D.,
Wich Olarnpiriyakul, M.D., Ph.D., Khanin Iamthanaporn, M.D.

Department of Orthopedics, Faculty of Medicine, Prince of Songkla University, Hat Yai, Songkhla 90110, Thailand.

Received 30 June 2022 • Revised 6 August 2022 • Accepted 11 August 2022 • Published online 11 October 2022

Abstract:

Herein, is the described the case of a 60-year-old male with osteogenesis imperfecta (OI), presenting with an acetabulum fracture after low-energy trauma. Due to poor bone quality, the fracture configuration was unusual from a typical type of acetabulum fracture. This patient had severe impaction of articular on the femoral head and acetabulum, which was an unusual configuration pattern within the normal population. Definitive management required both fixation of the acetabulum, together with total hip replacement, with concerns in the quality of fixation.

Keywords: acetabulum fracture, osteogenesis imperfecta, single stage arthroplasty-fixation

Contact: Chulin Chewakidakarn, M.D.
Department of Orthopedics, Faculty of Medicine, Prince of Songkla University,
Hat Yai, Songkhla 90110, Thailand.
E-mail: chulinccc@yahoo.com

J Health Sci Med Res
doi: 10.31584/jhsmr.2022902
www.jhsmr.org

© 2022 JHSMR. Hosting by Prince of Songkla University. All rights reserved.
This is an open access article under the CC BY-NC-ND license
(<http://www.jhsmr.org/index.php/jhsmr/about/editorialPolicies#openAccessPolicy>).

Introduction

Fractures of the acetabulum usually result from high mechanism injuries; such as car accidents or from falls from height. Fracture patterns are classified by column of involvement.¹ Open reduction and fixation are the treatments of choice in displaced fractures, in order to reduce and stabilize the articular surface.² Osteogenesis imperfecta (OI) is a rare disease that has an affect on abnormal collagen formations, and the severity of clinical manifestations vary from mild to lethal.^{3,4} Poor bone stock, soft tissue problems and bleeding tendency, due to vascular endothelial fragility, are major concerns for the operating orthopedic surgeon.⁵⁻⁷ Fracture patterns in OI may present with special patterns of configuration other than the currently used classifications.⁸ There have been reports of a few cases with acetabulum fracture in OI patients having involved both columns, and herein, is a report on different patterns of an acetabulum fracture in an OI patient treated with single stage fixation and total hip arthroplasty (THA).

Ethical approval

The patient provided written informed consent to share his case details, and any accompanying images published. Human Research Ethic Committee, Faculty of Medicine, Prince of Songkla University provided its approval to publish the case details. The patient's personal information remains confidential. There was no cost, payment made or harm to the patient as a result of this study.

Case report

A 60-year-old man was referred from another hospital with right hip pain, deformity and being unable to walk. Two days before this admission, he fell down on his right hip while traveling aboard, and was subsequently transferred to our hospital. He was diagnosed as having Osteogenesis Imperfecta (Silence type I) by our hospital endocrinologist; presenting with multiple episodes of severe

back pain from spinal osteoporotic collapse. He had blue sclera, right sensorineural hearing loss and no history of extremities fracture. Current medications were Alendronate, calcium and vitamin D.

Radiographic imaging of hip revealed right an acetabulum fracture, with protusio acetabuli, acetabular surface impaction in the iliac oblique view and posterior wall fracture with intact anterior and posterior column (Figure 1). Computed tomography (CT) showed fracture roof, medial and posterior wall and posterior column of the right acetabulum. Anterior femoral head impaction was noted. Severe comminution of wall fragments were better seen in the CT scan (Figure 1). The acetabulum fracture was classified as: posterior wall with posterior column fracture, according to the Judet and Letournel classification. THA was planned due to unreconstructed wall fracture and articular impaction on both the acetabular and femoral sides.

Definitive surgery was performed on post injury day 10. Then the patient was set in the left lateral decubitus position on the radiolucent table. A standard Kocher–Langenbach approach was made, with around a 15 centimeters length skin incision over the tip of the greater trochanter towards posterior superior iliac of the spine. Short, external rotators were cut close to its insertion. Posterior wall fragments were reduced, using the femoral head as a template for reduction, and temporary fixed with multiple K-wires. 11-holes, with 3.5 mm reconstruction plates were contoured and fixed into the ilium proximally and ischial tuberosity; distally. Supplement fixation of the posterior column was performed with small hand fragment locking plates, because of the narrow width of the remaining posterior column.

The hip was dislocated posteriorly; an impacted and deformed femoral head was noticed. Neck cutting was made at around 1 cm from the lesser trochanter. The acetabular side was prepared first, cancellous chips; harvested from the resected femoral head were filled within acetabular

bone defects, then progress reaming of the acetabulum was performed. The actual size of the acetabular cap was replaced with the same size of reaming and augmented with multiple screws aimed into the intact ilium: appropriate stability of the cup could be archived. A cemented femoral stem was inserted after leg length measurement and hip stability testing was confirmed. Intra-operative blood loss was estimated around 2,100 mL. The patient received 6

units of packed red cells and 3 units of fresh, frozen plasma. Post-operatively, the patient was able to walk with foot-touch weight bearing for 6 weeks, then progressive weight bearing thereafter. Radiographic analysis showed stable construction without signs of loosening or mechanical failure at 2 years follow up (Figure 2): the patient was able to walk independently without pain

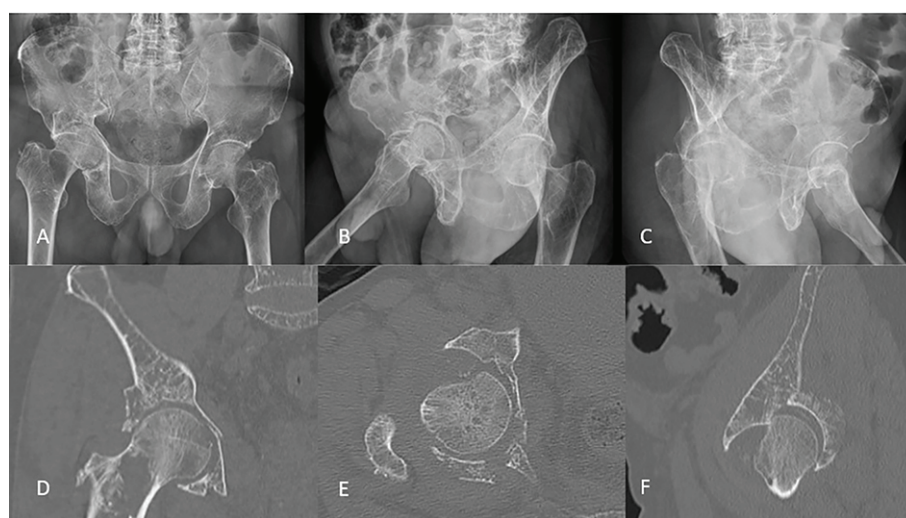


Figure 1 Plain radiographs of the pelvis, AP view (A), iliac oblique view (B), obturator oblique view (C) and CT scan of right hip in coronal plane (D), axial (E) and sagittal (F) shows a right acetabulum fracture with impacted acetabular roof and femoral head, displaced posterior wall and protusio acetabuli

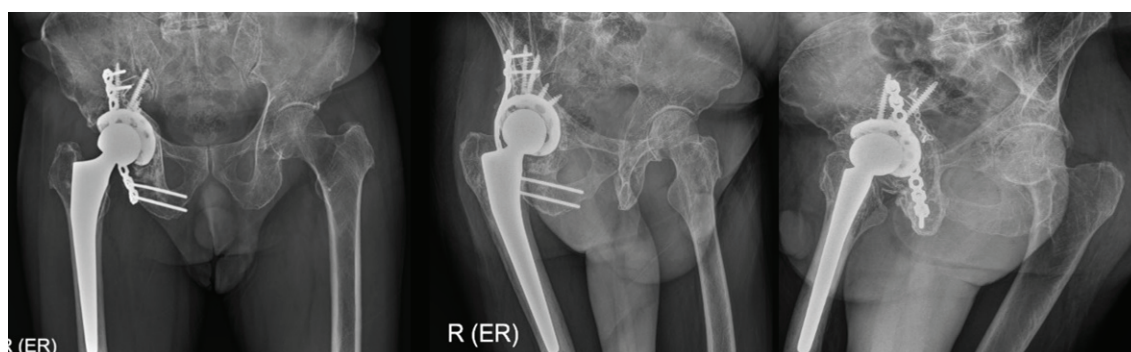


Figure 2 Right AP (left), obturator oblique (middle) and iliac oblique (right) post-operative radiographs at 2-year follow-up

Discussion

OI is a rare disease, and in its lethal form can cause intrauterine death, while a mild form may present with fragility fractures in adulthood.⁷ Poor bone quality as well as bone stock, bleeding diathesis and poor soft tissue conditions led to fractures easily, and difficulty with fracture stabilization.^{4–6}

Acetabulum fractures resulting by falling from a standing height level indicate poor bone strength in itself. There have been few cases reported of acetabulum fractures in OI patients: fracture classification being T–type, both column fractures; however, none have reported posterior column with posterior wall fracture. Darmanis and Bircher have reported 2 cases with T–type configuration, according to the Judet and Letournel classification.⁹ Liporace et al and Medici et al have also presented one case with one side both column fracture of the acetabulum and both sides of both column fractures, respectively.^{10,11} All cases were a result from low–energy mechanisms in non–advanced ages. Very severe comminution and femoral head impaction in our case may resulted from marked osteopenia seen in plain films and CT scans due to advanced age besides of OI.

Due to the small size of femoral head impaction and young aged patients, Darmanis and Bircher decided to reconstruct fractures with open reduction and fixation; rather than arthroplasty.⁹ Even with marked protusio acetabuli and comminution of the medial wall, Medici et al also performed Open Reduction and Internal Fixation (ORIF) to restore hip mechanics and bone stock, to avoid complications of arthroplasty in his young patients.¹¹ Due to advanced age and impaction on both the acetabular and femoral head, our patient was suitable for an acute setting: primary THA with bone fixation to support overall construct.¹²

Stable fixation of the acetabular cup is crucial for THA. In our case, we used a multi–hole, cementless acetabular shell secured with multiple screws, after filling

the medial defect with autograft and buttress fixation of the posterior wall and column. ORIF of the posterior wall was not aimed for anatomical reduction, but rather only for adding posterior stability of the acetabular cup. Although, cementless femoral stems have better long–term outcomes after primary THA, a cemented stem was elected, due to poor bone quality that might fracture or crack during cementless stem insertion.¹³ Both ORIF of the acetabulum and THA are major operations that may associated with marked amounts of intra–operative blood loss. This problem is more serious in OI patients, which have problems with abnormal capillary endothelial walls. Peri–operative management of hemodynamic status; such as preparation of colloid solutions and blood components are crucial to replace blood loss.

Post–operative prophylaxis of heterotrophic ossification is recommended after posterior hip approach in order to prevent hypertrophic bone formation. Ramaswamy et al, reported large HO in OI patients with recurrent fractures, and used the hypertrophic bone as an additive space for fixation stability.¹⁴ Liporace et al, did not prescribe any prophylaxis fixation for his patients and no significant HO was observed at the final follow up.¹⁰ In our opinion, the use of oral indomethacin for 6 weeks as prophylaxis of HO, because of stability of the overall construct can be archived, and there is concern of hip joint stiffness if HO is formed was recommended. The patient was allowed ambulation, with foot–touch weight bearing and an assisting device. After 2 years of follow up, no HO was observed, and the patient has a pain free hip joint, and can ambulation freely without need of a gait aid.

Conclusion

Acetabulum fractures in OI patients are rare. Understanding both fracture treatment strategies and systemic manifestation of OI are essential in all of pre, peri and post–operative management in order to minimize

complication in such patients. Single-stage fixation and THA is one of the available options in selected patients.

Funding sources

This research did not receive any specific grant from funding agencies in the public, commercial, or not-for-profit sectors.

Conflict of interest

The author has no conflict of interest to disclose.

References

1. Matta JM, Merritt PO. Displaced acetabular fractures. Clin Orthop Relat Res 1988;230:83–97.
2. Wright R, Barrett K, Christie M, Johnson KD. Acetabular fractures: long-term follow up of open reduction and internal fixation. J Orthop Trauma 1994;8:397–403.
3. Basel D, Steiner RD. Osteogenesis imperfecta: recent findings shed new light on this once well-understood condition. Genet Med 2009;11:375–85.
4. Van Dijk FS, Cobben JM, Kariminejad A, Maugeri A, Nikkels PGJ, Van Rijn RR, et al. Osteogenesis imperfecta: a review with clinical examples. Mol Syndromol 2011;2:1–20.
5. Edge G, Okafor B, Fennelly ME, Ransford AO. An unusual manifestation of bleeding diathesis in a patient with osteogenesis imperfecta. Eur J Anaesthesiol 1997;14:215–9.
6. Keegan MT, Whatcott BD, Harrison BA. Osteogenesis imperfecta, perioperative bleeding, and desmopressin. Anesthesiology 2002;97:1011–3.
7. Roberts TT, Cepela DJ, Uhl RL, Lozman J. Orthopaedic considerations for the adult with osteogenesis imperfecta. J Am Acad Orthop Surg 2016;24:298–308.
8. Letournel E. Letournel E. Acetabulum fractures: classification and management. Clin Orthop Relat Res 1980;151:81–106.
9. Darmanis S, Bircher M. Fractures of the acetabulum in osteogenesis imperfecta. J Bone Joint Surg Br 2006;88:670–2.
10. Liporace FA, Yoon RS, Frank MA, Maurer JP, Gaines RJ. Single-stage total hip arthroplasty and fracture fixation for a both column acetabular fracture in type I osteogenesis imperfecta. Injury 2011;42:1184–7.
11. Medici A, Di Salvatore MG, Pezzella R, Fidanza A, De Simone AM, Calvisi V. Bilateral fractures of acetabulum in a young girl with osteogenesis imperfecta and epilepsy. Trauma Case Reports 2020;25:6–10.
12. Boraiah S, Ragsdale M, Achor T, Zelicofer S, Asprinio DE. Open reduction internal fixation and primary total hip arthroplasty of selected acetabular fractures. J Orthop Trauma 2009;23:243–8.
13. Zhang C, Yan CH, Zhang W. Cemented or cementless fixation for primary hip arthroplasty—evidence from The International Joint Replacement Registries. Ann Jt 2017;2:57.
14. Ramaswamy R, Kosashvili Y, Cameron H. Bilateral total hip replacement in osteogenesis imperfecta with hyperplastic callus. J Bone Joint Surg Br 2009;91:812–4.