

## Isolated Third Cranial Nerve Palsy: Aetiology – Clinical Profile and Recovery at a Tertiary Neuro–ophthalmology Centre on the East Coast Peninsular of Malaysia

Masnon Nurul–Ain, M.D., M.S.<sup>1,2</sup>, Wan Hazabbah Wan Hitam, M.D., M.S.<sup>1</sup>,  
Ismail Shatriah, M.D., M.S.<sup>1</sup>, Sanisah Abdul Halim, M.D., M.Med.<sup>3</sup>

<sup>1</sup>Department of Ophthalmology and Visual Science, School of Medical Sciences, Health Campus, Universiti Sains Malaysia, 16150 Kubang Kerian, Kelantan, Malaysia.

<sup>2</sup>Department of Ophthalmology, Hospital Kuala Lumpur, 50586, Kuala Lumpur, Malaysia.

<sup>3</sup>Department of Medicine, School of Medical Sciences, Health Campus, Universiti Sains Malaysia, 16150 Kubang Kerian, Kelantan, Malaysia.

Received 8 June 2022 • Revised 19 July 2022 • Accepted 4 August 2022 • Published online 6 October 2022

### Abstract:

**Objective:** This study aimed to study the aetiologies, clinical profile and recovery of isolated third cranial nerve palsy (ITCNP) patients, at a tertiary neuro–ophthalmology center on the East Coast Peninsular of Malaysia.

**Material and Methods:** This was a retrospective study, involving 33 patients with newly diagnosed ITCNP, who were treated at the Hospital of the Universiti Sains, Malaysia; from January 2018 to December 2019, with a follow up period ranging from 18 to 24 months. The demographic data, clinical features and aetiologies of the patients were analysed.

**Results:** Patients' ages ranged from 14 to 79 years (mean: 48, 50 years of age). The main aetiology was microvascular ischemia (39.4%), followed by trauma (30.3%), aneurysm (15.2%), tumour (9.1%) and undetermined cause (6.1%). Neuroimaging was performed for those indicated cases; with either computed tomography (CT), CT angiography, digital subtraction angiography, magnetic resonance imaging (MRI) with contrast or MRI angiography. Two-thirds of the patients (66.7%) had periorbital pain, which included 30.8% of patients with microvascular ischemia and 60.6% had pupil involvement; which was also found in 23.1% of patients with microvascular ischemia. Complete external third nerve palsy occurred in 18.2% of patients, and aberrant regeneration was observed in 36.4% of patients. Complete recovery occurred in 48.5%, of all patients, having microvascular ischemia and undetermined causes.

**Contact:** Prof. Wan Hazabbah Wan Hitam, M.D., M.S.  
Department of Ophthalmology and Visual Science, School of Medical Sciences,  
Health Campus, Universiti Sains Malaysia 16150 Kubang Kerian, Kelantan, Malaysia.  
E-mail: hazabbah@usm.my

J Health Sci Med Res .....  
doi: 10.31584/jhsmr.2022901  
www.jhsmr.org

© 2022 JHSMR. Hosting by Prince of Songkla University. All rights reserved.  
This is an open access article under the CC BY–NC–ND license  
(<http://www.jhsmr.org/index.php/jhsmr/about/editorialPolicies#openAccessPolicy>).

**Conclusion:** The aetiologies, clinical profile and recovery of ITCNP patients in our institution are comparable to those reported in other previous studies. Patients with microvascular ischemia may also demonstrate periorbital pain and anisocoria. Neuroimaging remains the gold standard and the best tool via which to exclude other sinister and life-threatening aetiologies.

**Keywords:** aetiology, clinical profile, isolated third cranial nerve palsy, recovery

## Introduction

Ocular motor cranial nerve palsies are common presentations in ophthalmology clinics worldwide, and are a leading cause of visual morbidity. Among the ocular motor cranial nerves, the third nerve has important clinical relevance, because its presence may be the only sign of an intracranial aneurysm or neuro-ophthalmological emergency; which can be life-threatening.<sup>1-3</sup> The third cranial nerve participates in eyeball movement; via extraocular muscle control for adduction, elevation and depression due to the innervation of the recti muscles; namely the medial rectus, superior rectus, inferior rectus and inferior oblique. The third nerve is also responsible for lid opening, through the function of the levator palpebrae superioris muscle. It is also responsible for pupillary constriction, because it carries the parasympathetic fibres to the smooth muscles of the pupillary sphincter and ciliary muscle.<sup>4</sup>

The evaluation of the aetiology of an isolated third cranial nerve palsy (ITCNP) remains a diagnostic challenge, and a delay in the diagnosis of life-threatening cases may lead to significant morbidity and even death. Hence, the selection of cases for advanced neuroimaging should be justified based on clinical characteristics. The identification of benign aetiologies; especially microvascular ischemia, may reduce unnecessary referrals to interventional neurologists and neurosurgeons.

Although, studies discussing the profile and aetiologies of ocular motor nerve palsies are widely available, those with a specific focus on ITCNP; especially

among the Malaysian population, remain limited. Therefore, this study was conducted to describe the aetiologies, clinical profile and recovery of ITCNP patients at a tertiary neuro-ophthalmology centre on the East Coast Peninsular of Malaysia.

## Material and Methods

A retrospective review was performed on 33 patients, being treated for newly diagnosed ITCNP (within one month of onset), at the Hospital of Universiti Sains, Malaysia; from January 2018 to December 2019, with a follow-up period ranging from 18 to 24 months. The study was conducted according to the Declaration of Helsinki, and the study protocol was approved by the Research and Ethical Committee, School of Medical Sciences, Universiti Sains Malaysia.

Hospital Universiti Sains Malaysia is located on the North-East Peninsular of Malaysia, It is a teaching hospital in Malaysia, equipped with neurology, neuro-ophthalmology, neurosurgery and interventional radiology services. All newly diagnosed cases of ITCNP; from 1 January 2018 through 31 December 2019, at the Ophthalmology Clinic, Hospital Universiti Sains Malaysia were identified using an electronic record system. All medical records were reviewed to confirm the demographics, presenting symptoms, clinical characteristics, aetiologies, treatments and recovery of ITCNP patients.

The selection criteria for this study were a diagnosis of ITCNP based on ocular examination findings, along

with ptosis and restriction of up-gaze, down-gaze and adduction, with either pupillary dilatation or pupillary sparing. Patients were excluded if they had other cranial nerve or neurological involvement other than periorbital pain or headache upon presentation, or conditions that mimic third nerve palsy; such as, orbital wall fracture, myasthenia gravis and thyroid orbitopathy.

Data on patients' demographics, medical risk factors, presenting symptoms, relevant history, periorbital pain or severe headache were collected. The clinical characteristics of third nerve palsy in reference to the pupil; whether it was involved (anisocoria) or spared, ptosis and extraocular muscle movement, complete or partial external third nerve palsy and signs of aberrant regeneration during follow-up were documented. Anisocoria or pupil involvement was defined as dilatation of 1 mm or more, as compared to the other eye's pupil. Complete external third nerve palsy was defined by complete ptosis and the complete limitation of adduction, up-gaze and down-gaze. Aberrant regeneration occurs when there is a synkinetic movement of the muscles innervated by the third nerve; based on the evidence of: a) the elevation of the upper eyelid on downward gaze or adduction, b) the adduction of the eye on attempted vertical gaze, c) the limited elevation and depression of the eye with the retraction of the globe on attempted vertical gaze or d) pupillary constriction with extraocular muscle movement.

Neuroimaging findings; based on computed tomography (CT), CT angiography (CTA), digital subtraction angiography (DSA), magnetic resonance imaging (MRI) brain with contrast or MRI angiography (MRA) and other relevant investigation results, were reviewed. This included a lipid panel, haemoglobin A1c, full blood picture, erythrocyte sedimentation rate (ESR), C-reactive protein (CRP), venereal disease research laboratory (VDRL), antinuclear antibody (ANA), rheumatoid factor (RhF) and complement levels. The treatments received by the patients were carefully documented. Full recovery was closely observed and charted. The data were analysed using the Statistical

Package for Social Sciences Version 26.0 (SPSS Inc, Chicago, IL, USA).

## Results

We documented 33 patients, 31 Malay and two Chinese patients, with ITCNP, who presented to our institution during the study period. There were 15 males and 18 females (ratio 0.8:1.0), and their ages ranged from 14 to 79 years (mean: 50.48 years). The majority of patients (36.4%) fell between 51 and 60 years old; And all patients had unilateral presentations. Eighteen patients (54.5%) had medical risk factors; specifically diabetes mellitus, hypertension and dyslipidemia, either in isolation or combined, while 15 patients (45.5%) were previously well, without any comorbidities.

The majority of our ITCNP cases (39.4%, 13 patients) were attributed to microvascular ischemia, while 30.3% (ten patients) developed ITCNP following trauma; all as the result of traffic accidents. Aneurysm was observed in five patients (15.2%). These consisted of two with posterior communicating (PCOM) artery aneurysm, two with internal carotid artery (ICA) aneurysm and one patient with basilar artery aneurysm. Additionally, 9.1% (three patients) were noted to have tumours, which comprised of two meningiomas and one pituitary macroadenoma. The remaining two patients (6.1%) had undetermined causes of ITCNP.

Twenty-four patients (72.8%) presented due to ptosis, while 13 patients (39.4%) presented due to diplopia. Periorbital pain was present in 22 patients (66.7%), with five patients (15.2%) having severe headaches. Partial external third nerve palsy was more common than complete external third nerve palsy (27 patients, 81.8%). Twenty patients (60.6%) displayed pupillary involvement and anisocoria. Aberrant regeneration was seen in 36.4% of patients (12), while complete recovery occurred in 48.5% of patients (16). CT brain was performed on all patients with headache or periorbital pain, anisocoria, traumatic cases and also those

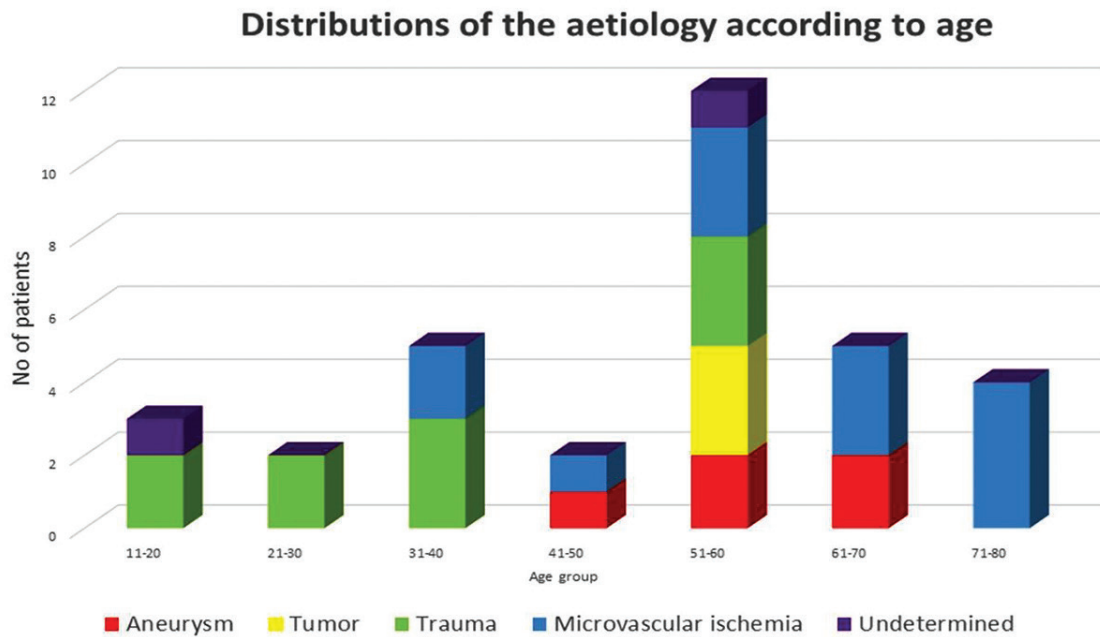
with undetermined causes. In our setting, CTA and DSA are performed for further evaluation of aneurysm. MRI brain with contrast was performed for further evaluation of tumour cases, and combined with MRA was performed for further evaluation of stroke cases.

The demographics of our subjects as well as the clinical characteristics of their third nerve palsy are summarised in Table 1. Figure 1; shows the distribution of aetiology according to age.

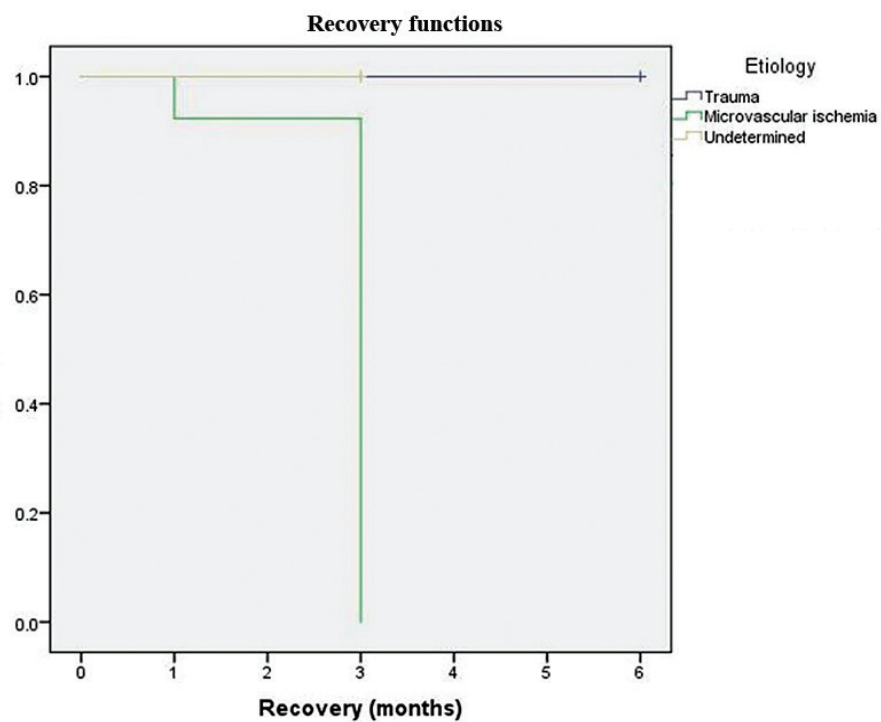
Our study showed that the demographic profiles, in terms of age, gender and race, do not statistically differ between etiologies. Periorbital pain is a typical characteristic of all patients with aneurysm, tumours, trauma and it is was also present in 30.8% of patients with microvascular ischemia. Severe headaches were exclusively experienced by patients with aneurysm. Pupillary involvement mainly occurred in the aneurysm, trauma and tumour group; however it was also demonstrated by 23.1% of patients with microvascular ischemia. Medical risk factors; especially diabetes mellitus and hypertension, were not only inherent in all patients with microvascular ischemia but also present in all patients with tumours and 40% of patients with aneurysms. The relationship between demographics, clinical features and medical risk factors for each aetiology are summarised in Table 2. A further analysis comparing the clinical features of microvascular ischemia with those of other aetiologies is provided in Table 3. A comparison between patients with complete recovery and non-recovery is shown in Table 4, which clearly shows that complete recovery mainly occurred in all patients with microvascular ischemia and undetermined causes. Severe headache, aberrant regeneration and aetiologies; due to aneurysms and tumours, were related to poor recovery. A Kaplan-Maier analysis was performed for the aetiological group. The pattern of the duration of complete recovery for the respective aetiologies is shown in Figure 2.

**Table 1** Demographic data and clinical characteristics of study patients (n=33)

Variables	Number (%)
Age (year)	
Mean±S.D.	50.48±16.61
Range	14–79
Age group	
11–20	3 (9.1)
21–30	2 (6.1)
31–40	4 (12.1)
41–50	4 (12.1)
51–60	12 (36.4)
61–70	6 (18.2)
71–80	2 (6.1)
Sex	
Male	15 (45.5)
Female	18 (54.5)
Race	
Malay	31 (93.9)
Chinese	2 (6.1)
Laterality	
Unilateral	33 (100.0)
Bilateral	0 (0.0)
Aetiology	
Microvascular ischemia	13 (39.4)
Trauma	10 (30.3)
Aneurysm	5 (15.2)
Tumour	3 (9.1)
Undetermined	2 (6.1)
Medical risk factor	
Yes	18 (54.5)
No	15 (45.5)
Symptom	
Ptosis	24 (72.8)
Diplopia	13 (39.4)
Periorbital pain	22 (66.7)
Severe headache	5 (15.2)
Pupil involvement	
Pupil involvement	20 (60.6)
Pupil sparing	13 (39.4)
External third nerve palsy	
Complete	6 (18.2)
Partial	27 (81.8)
Aberrant regeneration	
Yes	12 (36.4)
No	21 (63.6)
Complete recovery	
Yes	16 (48.5)
No	17 (51.5)



**Figure 1** Distributions of the aetiology according to age (years)



**Figure 2** Distributions of recovery according to aetiology. The time to recovery distributions for the three groups were statistically, significantly different,  $\chi^2(2)=11.88$ , p-value=0.003

**Table 2** Demographic, characteristics, medical risk factors and recovery in relation to aetiology among patients with isolated third cranial nerve palsy, treated at Hospital, Universiti Sains Malaysia (n=33)

Variables	Trauma N (%)	Microvascular ischemia N (%)	Aneurysm N (%)	Tumor N (%)	Undetermined N (%)	p-value
No of patients	10 (30.3)	13 (39.4)	5 (25.2)	3 (9.1)	2 (6.1)	–
Age	35.8 (15.62)*	61.0 (11.01)*	56.8 (8.79)*	55.7 (3.51) *	32 (16.7) *	0.331 <sup>a</sup>
Gender						
Male	3 (30.0)	9 (69.2)	2 (40.0)	0 (0)	1 (50.0)	0.165 <sup>b</sup>
Female	7 (70.0)	4 (30.8)	3 (60.0)	3 (100.0)	1 (50.0)	
Race						
Malay	10 (100.0)	12 (92.3)	4 (80.0)	3 (100.0)	2 (100.0)	0.603 <sup>b</sup>
Chinese	0 (0)	1 (7.7)	1 (20.0)	0 (0)	0 (0)	
Periorbital pain						
Yes	10 (100.0)	4 (30.8)	5 (100.0)	3 (100.0)	0 (0)	<0.001 <sup>b</sup>
No	0 (0)	9 (69.2)	0 (0)	0 (0)	2 (100.0)	
Severe headache						
Yes	0 (0)	0 (0)	5 (100.0)	0 (0)	0 (0)	<0.001 <sup>b</sup>
No	10 (100.0)	13 (100.0)	0 (0)	3 (100.0)	2 (100.0)	
Pupil involvement						
Yes	9 (90.0)	3 (23.1)	5 (100.0)	3 (100.0)	0 (0)	0.001 <sup>b</sup>
No	1 (10.0)	10 (76.9)	0 (0)	0 (0)	2 (100.0)	
Complete external third nerve palsy						
Yes	0 (0)	5 (38.5)	1 (20.0)	0 (0)	0 (0)	0.139 <sup>b</sup>
No	10 (100.0)	8 (61.5)	4 (80.0)	3 (100.0)	2 (100.0)	
Aberrant regeneration						
Yes	7 (70.0)	0 (0)	3 (60.0)	2 (66.7)	0 (0)	0.003 <sup>b</sup>
No	3 (30.0)	13 (100.0)	2 (40.0)	1 (33.3)	2 (100.0)	
Medical risk factor						
Yes	0 (0)	13 (100.0)	2 (40.0)	3 (100.0)	0 (0)	<0.001 <sup>b</sup>
No	10 (100.0)	0 (0)	3 (60.0)	0 (0)	2 (100.0)	
Total medical risk factor						
Nil	10 (100.0)	0 (0)	3 (60.0)	0 (0)	2 (100.0)	0.001 <sup>a</sup>
1	0 (0)	5 (38.5)	1 (20.0)	0 (0)	0 (0)	
2	0 (0)	6 (46.2)	0 (0)	2 (66.7)	0 (0)	
3	0 (0)	2 (15.4)	1 (20.0)	1 (33.3)	0 (0)	
Diabetes Mellitus						
Yes	0 (0)	11 (84.6)	1 (20.0)	2 (66.7)	0 (0)	<0.001 <sup>b</sup>
No	10 (100)	2 (15.4)	4 (80.0)	1 (33.3)	2 (100.0)	
Hypertension						
Yes	0 (0)	10 (76.9)	2 (40.0)	2 (66.7)	0 (0)	0.003 <sup>b</sup>
No	10 (100.0)	3 (23.1)	3 (60.0)	1 (33.3)	2 (100.0)	
Dyslipidemia						
Yes	0 (0)	2 (15.4)	1 (20.0)	2 (66.7)	0 (0)	0.077 <sup>b</sup>
No	10 (100.0)	11 (84.6)	4 (80.0)	1 (33.3)	2 (100.0)	
Complete recovery						
Yes	1 (10.0)	13 (100.0)	0 (0)	0 (0)	2 (100.0)	<0.001 <sup>b</sup>
No	9 (90.0)	0 (0)	5 (100.0)	3 (100.0)	0 (0)	

Values are presented as total (%), \*presented as mean (S.D.)

<sup>a</sup>One-way ANOVA, <sup>b</sup>Chi-square test

**Table 3** The comparison of demographic, clinical characteristics and medical risk factors between patients with microvascular ischemia and other aetiologies of isolated third cranial nerve palsy (n=33)

Variable	Etiology		Total N (%)	p-value
	Microvascular Ischemia N (%)	Others N (%)		
Age	61 (11.01) <sup>*</sup>	43.65 (16.22) <sup>*</sup>	50.48 (16.41) <sup>*</sup>	0.002 <sup>b</sup>
Gender				
Male	9 (69.2)	6 (30.0)	15 (45.5)	0.038 <sup>a</sup>
Female	4 (30.8)	14 (70.0)	18 (54.5)	
Race				
Malay	12 (92.3)	19 (95.0)	31 (93.9)	>0.950 <sup>a</sup>
Chinese	1 (7.7)	1 (5.0)	2 (6.1)	
Periorbital pain				
Yes	4 (30.8)	18 (90.0)	22 (66.7)	0.001 <sup>a</sup>
No	9 (69.2)	2 (10.0)	11 (33.3)	
Severe headache				
Yes	0 (0)	5 (25.0)	5 (15.2)	0.131 <sup>a</sup>
No	13 (100.0)	15 (75.0)	28 (84.8)	
Pupil involvement				
Yes	3 (23.1)	17 (85.0)	20 (60.6)	0.001 <sup>a</sup>
No	10 (76.9)	3 (15.0)	13 (39.4)	
Complete external third nerve palsy				
Yes	5 (38.5)	1 (5.0)	6 (18.2)	0.025 <sup>a</sup>
No	8 (61.5)	19 (95.0)	27 (81.8)	
Aberrant regeneration				
Yes	0 (0)	12 (60.0)	12 (36.4)	0.001 <sup>a</sup>
No	13 (100.0)	8 (40.0)	21 (63.6)	
Medical risk factor				
Yes	13 (100.0)	5 (25.0)	18 (54.5)	<0.001 <sup>a</sup>
No	0 (0)	15 (75.0)	15 (45.5)	
Total medical risk factor				
Nil	0 (0)	15 (45.5)	15 (45.5)	<0.001 <sup>b</sup>
1	5 (38.5)	1 (5.0)	6 (18.2)	
2	6 (46.2)	2 (10.0)	8 (24.2)	
3	2 (15.4)	2 (10.0)	4 (12.1)	
Diabetes mellitus				
Yes	11 (84.6)	3 (15.0)	14 (42.4)	<0.001 <sup>a</sup>
No	2 (15.4)	17 (85.0)	19 (57.6)	
Hypertension				
Yes	10 (76.9)	4 (20.0)	14 (42.4)	0.003 <sup>a</sup>
No	3 (23.1)	16 (80.0)	19 (57.6)	
Dyslipidemia				
Yes	2 (15.4)	3 (15.0)	5 (15.2)	>0.950 <sup>a</sup>
No	11 (84.6)	17 (85.0)	28 (84.4)	

<sup>\*</sup>Mean (S.D.) reported; p-value was based on <sup>a</sup>independent t-test<sup>b</sup>Pearson chi-square applied

**Table 4** Comparison of demographic, characteristics, medical risk factors and aetiology between patients with complete recovery, and non-recovery for isolated third cranial nerve palsy (n=33)

Variables	Complete recovery N (%)	Non-recovery N (%)	p-value
Age	56.94 (14.63)*	44.41 (16.44)*	0.612 <sup>a</sup>
Gender			
Male	10 (62.5)	5 (29.4)	0.084 <sup>b</sup>
Female	6 (37.5)	12 (70.6)	
Race			
Malay	15 (93.8)	16 (94.1)	>0.95 <sup>b</sup>
Chinese	1 (6.3)	1 (5.9)	
Periorbital pain			
Yes	5 (31.3)	17 (100.0)	<0.001 <sup>b</sup>
No	11 (68.8)	0 (0)	
Severe headache			
Yes	0 (0)	5 (29.4)	0.044 <sup>b</sup>
No	16 (100.0)	12 (70.6)	
Pupil involvement			
Yes	3 (18.8)	17 (100.0)	<0.001 <sup>b</sup>
No	13 (81.3)	0 (0)	
Complete external third nerve palsy			
Yes	5 (31.3)	1 (5.9)	0.085 <sup>b</sup>
No	11 (68.8)	16 (94.1)	
Aberrant regeneration			
Yes	0 (0)	5 (29.4)	<0.001 <sup>b</sup>
No	16 (100.0)	12 (70.6)	
Medical risk factor			
Yes	13 (81.3)	12 (70.6)	0.005 <sup>b</sup>
No	3 (18.8)	5 (29.4)	
Total medical risk factor			
Nil	3 (18.8)	12 (70.6)	0.018 <sup>b</sup>
1	5 (31.3)	1 (5.9)	
2	6 (37.5)	2 (11.8)	
3	2 (12.5)	2 (11.8)	
Diabetes Mellitus			
Yes	11 (68.8)	3 (17.6)	0.005 <sup>b</sup>
No	5 (31.3)	14 (82.4)	
Hypertension			
Yes	10 (62.5)	4 (23.5)	0.037 <sup>b</sup>
No	6 (37.5)	13 (76.5)	
Dyslipidemia			
Yes	2 (12.5)	3 (17.6)	>0.950 <sup>b</sup>
No	14 (87.5)	14 (82.4)	
Aetiology			
Trauma	1 (6.3)	9 (52.9)	<0.001 <sup>b</sup>
Microvascular Ischemia	13 (81.3)	0 (0)	
Aneurysm	0 (0)	5 (29.4)	
Tumor	0 (0)	3 (17.6)	
Undetermined	2 (12.5)	0 (0)	

\*Mean (S.D.) reported; p-value was based on <sup>a</sup>t-test<sup>b</sup>Chi-square test



## Discussion

The age and gender adjusted annual incidence of acquired third nerve palsy was reported to be 3.71 to 4, per 100,000 person per year, with the overall incidence increasing with age.<sup>5,6</sup> All of our ITCNP cases were acquired cases, meaning that none of our patients had congenital palsy. Our mean age group of  $50.48 \pm 16.61$  years is consistent with the findings of other retrospective studies.<sup>1-3,7,8</sup> The occurrence of ITCNP is more common in older patients, with only one prospective study finding no difference in the frequency of ITCNP between the younger and older age groups (less than 50 years versus 50 years and older).<sup>9</sup> We demonstrated that the incidence of ITCNP is not significantly different between males and females, which is similar to most previously reported studies.<sup>1-3,5-9</sup> However, it is interesting to note that some research reports a higher rate of occurrence in males (2.5 to 3 times higher as compared to females); especially in the younger age group.<sup>10-12</sup> All of our patients demonstrated unilateral palsy. Bilateral involvement is rare, occurring in less than 10% of patients with ITCNP, with various aetiologies; including, midbrain cavernous malformation, pituitary apoplexy and giant cell arteritis.<sup>13,14</sup>

Previous studies have shown discrepancies in the distribution of underlying aetiologies of ITCNP. These discrepancies may be due to differences in the study populations, study designs or inclusion criteria applied. Our results showed that the most common cause of ITCNP was microvascular ischemia (39.4%), followed by trauma (30.3%), aneurysms (15.2%), tumours (9.1%) and undetermined causes (6.1%).

Microvascular ischemia is the leading cause of ITCNP in many studies, and it occurs in 20% to 53% of the general population.<sup>2,7,9</sup> In a study conducted with patients 50 years and above, the incidence of microvascular ischemia increased to more than 86% of the study population.<sup>9,15-16</sup> Because the prevalence of diabetes has been rising rapidly, which also involves younger patients, we note that Phulje

et al. found the highest percentage of microvascular ischemia (58.1%) in young patients (aged  $39.3 \pm 14.2$  years).<sup>10</sup>

Trauma was the second leading cause of ITCNP in our study (30.3%); especially affecting patients in the young age group. A higher number of traumatic ITCNP was previously reported; especially in paralytic strabismus studies (43–49%).<sup>8,17</sup> In fact, ITCNP may occur in cases of mild head injury, without any neuroimaging abnormality.<sup>18-19</sup> Several mechanisms have been described, either an expanding lesion; such as extradural or subdural haemorrhage, or partial rootlet avulsion, direct traction injury, direct vascular compression or indirect injury due to an impaired blood supply.<sup>19</sup>

The incidence of aneurysm as the aetiology of ITCNP is variable in literatures. Nevertheless, surgical third nerve palsy is an important warning sign prior to the rupture of an aneurysm: a neurological emergency that is life-threatening. We found that 15.2% of our patients had aneurysms. A higher incidence of aneurysms causing ITCNP have been reported, up to 40%<sup>1,2</sup>, while lower incidence rates (1.5–7.5%) have been reported by others.<sup>9-11,20,21</sup> Posterior circulation and PCOM artery aneurysms carry a higher risk of rupture as compared to aneurysm located in the internal carotid artery (ICA), anterior communicating or anterior cerebral artery and middle cerebral artery (MCA).<sup>22</sup> In our series; however, patients with PCOM, basilar tip and ICA aneurysm presented early, without rupture. Ruptured aneurysms with subdural haemorrhage consisted of two cases of MCA aneurysm; however, the limited number of patients in our study is not reflective of the risk of aneurysm rupture within our population as a whole. The size of the aneurysm has also been reported to be an important predictive factor for aneurysm rupture, with higher rupture rates being associated with a larger aneurysm size.<sup>22</sup> Cavernous aneurysms may also present with ITCNP<sup>6</sup>, potentially without pupillary involvement upon the initial presentation; however, this was not seen in our patients.

Among our patients, 9.1% had tumours manifesting as ITCNP. These consisted of two cases of meningioma and one pituitary adenoma. While ITCNP is not a common finding in tumours, meningioma and pituitary adenoma are the most common tumours causing ITCNP; as reported in previous studies. Others have reported that ITCNP may also occur due to nasopharyngeal carcinoma, oculomotor schwannoma, malignant peripheral nerve sheath tumours and temporal lobe tumours (anaplastic astrocytoma and glioblastoma multiforme).<sup>23-26</sup> The highest incidence of ITCNP due to tumours was reported to be 13.6%.<sup>12</sup> Patients with tumours tend to present with complex ophthalmoplegia or mixed cranial nerve palsies, due to the tumour compression.

Two patients in our series (6.1%) had undetermined causes, with normal neuroimaging and a thorough blood investigation. It is interesting to note that, despite high-resolution MRI and further blood investigations, undetermined causes still account for 10.4–26.9% of patients in previous studies.<sup>3,8,9,20,21</sup>

CT brain scanning can be used as a primary neuro-imaging tool in ITCNP cases; especially for those with headaches, periorbital pain, anisocoria, trauma, infective, inflammatory and infiltrative cases. Further evaluation with CTA is indicated for aneurysm, and CTA may also provide detailed information for stroke cases. DSA remains as a gold standard for a detailed assessment of aneurysm. MRI with contrast is superior to CT scanning in terms of soft tissue resolution, for detailed assessment of tumours, infective, inflammatory and infiltrative cases, and combined with a MRA can offer more detailed information in stroke cases.<sup>2,3,5-16</sup>

None of our patient had ITCNP due to giant cell arteritis, infection and infiltration or inflammatory cause due to neurosarcoidosis, Behcet disease or Tolosa Hunt Syndrome. ITCNP has been reported to occur with various infections; including, COVID-19,

tuberculosis, syphilis, toxoplasmosis, herpes simplex, zoster, fusobacterium, streptococcus pyogenes, cysticercosis, Lyme disease, group B streptococcus, Epstein-Barr virus, parvovirus, cryptococcus and neurobrucellosis, in either immunocompetent or immunocompromised patients.<sup>9-12,21,27</sup>

Additionally, ITCNP has been reported as a consequence of sinusitis or odontogenic abscess. More importantly, ITCNP has also been reported to occur in diffuse large B cell lymphoma, Burkitt lymphoma, multiple myeloma and metastatic pancreatic carcinoma, which are important to exclude.<sup>28-30</sup> None of these were found in our patients during the study period.

Most of our patients presented with ptosis (72.8%), while some other studies found that diplopia or ocular deviation were more common.<sup>7,10,31</sup> Periorbital pain or headache occurred in two-thirds of our patients (66.7%). Although, periorbital pain or headache is more common in the aneurysm, trauma and tumour group, these symptoms were also experienced by 30.8% of our patients with microvascular ischemia. Other studies reported that the occurrence of periorbital pain in microvascular ischemia ranged from 15.6% to 88%.<sup>1,7,9,32</sup> In cases of microvascular ischemia, there will be ischemic demyelination with axonal sparing, which is associated with microvascular arteriosclerotic changes in the vasa nervorum. Sensory fibres from trigeminal ganglion cells course along the epineurial sheath of the third nerve. The activation of pain-sensitive endings within the sheath of the third nerve may give rise to ischemic pain.<sup>33</sup>

Pupillary involvement occurred in 60.6% of our patients. Pupillary involvement occurs when pupillary parasympathetic fibres that travel superficially at the periphery along the medial portion of the third nerve are affected.<sup>3</sup> Although, surgical causes due to aneurysms, tumours and trauma would usually lead to compression and damage of the parasympathetic fibres, pupillary involvement was also observed in 23.1% of our patients

with microvascular ischemia. Pupillary involvement in microvascular ischemia has been reported to occur at rates from 15% to 53.8% in the literatures.<sup>1,7,32</sup> The mechanism is attributed to parasympathetic dysfunction, in association with microvascular ischemia.<sup>32</sup> Aberrant regeneration was observed in our patients with aneurysms, trauma and tumours. In cases of aberrant regeneration, after the third nerve endoneurium is disrupted, the regenerating third nerve fibres no longer follow their previous paths; thus, not supplying their original terminal muscle. Instead, they regenerate aberrantly, being misdirected to other routes, causing the paradoxical co-contraction of the supplied muscles (lid, extraocular muscles or pupil) upon the firing of the nerve. The literature has shown that aberrant regeneration of third nerve may also occur in microvascular ischemia, Tolosa Hunt syndrome and Miller Fisher syndrome. Reversible aberrant regeneration was also reported following giant cell arteritis and ophthalmoplegic migraine.<sup>34</sup>

Complete recovery was reported to be as high as 68.4% for ITCNP in previous series.<sup>3</sup> This occurred in 48.5% of our patients, which consisted of all patients with microvascular ischemia and undetermined causes as well as in one patient with trauma. Microvascular ischemia had a good complete recovery rate, with 83–96% of cases fully resolving over a period of three to six months; as described in previous studies.<sup>1,6,9</sup> In microvascular ischemia, the presumed mechanism involves the thickening and hyalinisation of the nutrient vessels, resulting in the ischemic demyelination in a portion of the nerve. As time goes by, the area of ischemic demyelination subsequently undergoes remyelination, accounting for clinical recovery.<sup>35</sup> The delayed recovery in microvascular ischemia is related to the presence of more vasculopathic risk factors and also the presence of associated ischemic findings on the brain MRI.<sup>20,36</sup> Undetermined causes were also found to have a good chance of complete spontaneous recovery,

for which the prognosis is the best; as reported by some studies.<sup>20</sup> We documented the rate of complete recovery in traumatic cases as being 10%. Jeong et al. reported that traumatic third nerve palsy showed the lowest recovery rate compared to the fourth and sixth nerves.<sup>37</sup> Park et al. reported a complete recovery rate as high as 87.5% among cases of traumatic ocular motor palsy<sup>3</sup>, and small angle deviation upon presentation was shown to influence recovery.<sup>3,20</sup> Our series showed no recovery of ITCNP due to aneurysms and tumours. Literatures however have shown that 5.3% to 36.1% of patients with aneurysm experienced complete recovery<sup>1,38</sup>, while patients in the tumour group had the lowest recovery rate and took the longest time to recover.<sup>3,8,20</sup>

Our study results are limited by their retrospective nature, and our findings reflect a single institution review with a relatively small sample size. However, this study clearly showed that neuroimaging has a very important role in excluding sinister causes of ITCNP after a careful medical evaluation has been performed. Patients with known medical risk factors may not necessarily have ITCNP due to microvascular ischemia; however, they may harbour an impending rupture aneurysm or tumour. On the other hand, patients with microvascular ischemia may also demonstrate periorbital pain and anisocoria. Hence, we recommend that all patients with ITCNP be assessed properly and monitored closely. Additionally, prompt neuroimaging is warranted in a timely manner for these indicated cases in order to prevent mortality and catastrophic sequelae.

## Conclusion

Our study showed the highest incidence of microvascular ischemia in patients with ITCNP, with about one-third of such patients demonstrating symptoms of periorbital pain because of ischemia and pupillary involvement, due to parasympathetic dysfunction. We also noted that almost 50% of the patients with aneurysms

and more than 90% of the patients with tumours also had a known medical risk factor. Urgent neuroimaging, nevertheless plays an important role in confirming the diagnosis for those patients with periorbital pain and pupillary involvement; and thus, saving lives.

## Conflict of interest

None.

## References

- Green WR, Hackett ER, Schlezinger NS. Neuro-ophthalmologic evaluation of oculomotor nerve paralysis. *Arch Ophthalmol* 1964;72:154–67.
- Patel RD, Burdon MA. Isolated third cranial nerve palsies—modern management principles. *Eye (Lond)* 2022;36:232–1.
- Park UC, Kim SJ, Hwang JM, Yu YS. Clinical features and natural history of acquired third, fourth, and sixth cranial nerve palsy. *Eye* 2008;22:691–6.
- Joyce C, Le PH, Peterson DC. Neuroanatomy, cranial nerve 3 (oculomotor). In: StatPearls [monograph on the Internet]. Treasure Island (FL): StatPearls Publishing; 2022. Available from: <https://www.ncbi.nlm.nih.gov/books/NBK537126/>
- Jung EH, Kim SJ, Lee JY, Cho BJ. The incidence and etiologies of third cranial nerve palsy in Koreans: a 10-year nationwide cohort study. *Ophthalmic Epidemiol* 2020;27:460–7.
- Fang C, Leavitt JA, Hodge DO, Holmes JM, Mohney BG, Chen JJ. Incidence and etiologies of acquired third nerve palsy using a population-based method. *JAMA Ophthalmol* 2017;135:23.
- Çolpak AI, Çağlayan HB. Isolated third, fourth, and sixth cranial nerve palsies in the Turkish population: etiologic factors and clinical course. *Turk J Neurol* 2019;25:32–5.
- Ho TH, Lin HS, Lin MC, Sheu SJ. Acquired paralytic strabismus in Southern Taiwan. *J Chin Med Assoc* 2013;76:340–3.
- Choi KD, Choi SY, Kim JS, Choi JH, Yang TH, Oh SY, et al. Acquired ocular motor nerve palsy in neurology clinics: a prospective multicentre study. *J Clin Neurol* 2019;15:221–7.
- Phuljhele S, Dhiman R, Sharma M, Kusiya SK, Saxena R, Mahalingam K, et al. Acquired ocular motor palsy: current demographic and etiological profile. *Asia Pac J Ophthalmol (Phila)* 2020;9:25–8.
- Park KA, Oh SY, Min JH, Kim BJ, Kim Y. Acquired onset of third, fourth, and sixth cranial nerve palsies in children and adolescents. *Eye (Lond)* 2019;33:965–73.
- Park KA, Oh SY, Min JH, Kim BJ, Kim Y. Cause of acquired onset of diplopia due to isolated third, fourth, and sixth cranial nerve palsies in patients aged 20 to 50 years in Korea: A high resolution magnetic resonance imaging study. *J Neurol Sci* 2019;407:116546.
- Lazaridis C, Amir Torabi A, Cannon S. Bilateral third nerve palsy and temporal arteritis. *Arch Neurol* 2005;62:1766–68.
- Man BL, Fu YP. Isolated bilateral oculomotor nerve palsies due to a midbrain cavernous malformation. *BMJ Case Rep* 2013. doi: 10.1136/bcr-2013-201063.
- Chou KL, Galetta SL, Liu GT, Volpe NJ, Bennett JL, Asbury AK, et al. Acute ocular motor mononeuropathies: prospective study of the roles of neuroimaging and clinical assessment. *J Neurol Sci* 2004;219:35–9.
- Tamhankar MA, Bioussé V, Ying GS, Prasad S, Subramanian P, Lee MS, et al. Isolated third, fourth and sixth cranial nerve palsies from presumed microvascular versus other causes: a prospective study. *Ophthalmology* 2013;120:2264–9.
- de Camargo GB, Hida WT, Goldchmit M, Uesugui CF, de Souza-Dias CR. Paralytic strabismus: review of 24 years at "Santa Casa de São Paulo". *Arq Bras Oftalmol* 2007;70:585–7.
- Chen CC, Pai YM, Wang RF, Wang TL, Chong CF. Isolated oculomotor nerve palsy from minor head trauma. *Br J Sports Med* 2005;39:e34.
- Uberti M, Hasan S, Holmes D, Ganau M, Uff C. Clinical significance of isolated third cranial nerve palsy in traumatic brain injury: a detailed description of four different mechanisms of injury through the analysis of our case series and review of the literature. *Emerg Med Int* 2021;5550371.
- Kim K, Noh SR, Kang MS, Jin KH. Clinical course and prognostic factors of acquired third, fourth, and sixth cranial nerve palsy in Korean patients. *Korean J Ophthalmol* 2018;32:221–7.
- Kumar MP, Vivekanand U, Umakanth S, Yashodhara BM. A study of etiology and prognosis of oculomotor nerve paralysis. *Edorium J Neurol* 2014;1:1–8.
- Wiebers DO, Whisnant JP, Huston J, Meissner I, Brown RD Jr, Piepgras DG, et al. Unruptured intracranial aneurysms: natural history, clinical outcome, and risks of surgical and endovascular treatment. *Lancet* 2003;362:103–10.
- Sivakumar P, Palanive S, Debasis Gochait D, Olivia Hess O.

- Diagnostic challenges in a case of an isolated third nerve palsy. *Am J Ophthalmol Case Rep* 2020;18:100585.
24. Fard MA, Montgomery E, Miller NR. Complete, pupil-sparing third nerve palsy in a patient with a malignant peripheral nerve sheath tumor. *Arch Ophthalmol* 2011;129:813–14.
  25. Singh DK, Singh N, and Singh R. Isolated third nerve palsy: A rare presentation of high grade glioma. *Asian J Neurosurg* 2016;11:171–2.
  26. Sharma K, Kanaujia V, Lal H, Jaiswal S, Jaiswal AK. Isolated oculomotor nerve palsy: An unusual presentation of temporal lobe tumor. *Asian J Neurosurg* 2010;5:70–2.
  27. Finsterer J, Scorza FA, Scorza CA, Fiorini AC. COVID-19 associated cranial nerve neuropathy: a systematic review. *Bosn J Basic Med Sci* 2022;22:39–45.
  28. Khaleefah MM, Narayanan S, Al Dallal HA, Jones CM, Friedland RP, Palade AE. Isolated oculomotor nerve palsy as a manifestation of diffuse large B cell lymphoma: a case report. *Oncol Lett* 2020;20:285.
  29. Vaid T, Dhawan R, Aggarwal M, Tyagi S. Isolated third cranial nerve palsy as the first presentation of multiple myeloma. *BMJ Case Rep* 2021;14:e239917.
  30. Pecan PE, Ramey NA, Richard MJ, Bhatti MT. Metastatic pancreatic carcinoma to the orbital apex presenting as a superior divisional third cranial nerve palsy. *Clin Ophthalmol* 2012;6:1941–3.
  31. Mwanza JC, Ngweme GB, Kayembe DL. Ocular motor nerve palsy: a clinical and etiological study. *Indian J Ophthalmol* 2006;54:173–5.
  32. Jacobson DM. Pupil involvement in patients with diabetes-associated oculomotor palsy. *Arch Ophthalmol* 1998;116:723–7.
  33. Wilker SC, Rucker JC, Newman NJ, Biousse V, Tomsak RL. Pain in ischemic ocular motor cranial nerve palsies. *Br J Ophthalmol* 2009;93:1657–9.
  34. Harris G, Breazzano M, Shyu I, Donahue S, Lavin P. Oculomotor synkinesis (aberrant reinnervation of the third cranial nerve) associated with atypical Tolosa–Hunt Syndrome. *Neuroophthalmology* 2019;8:44:262–6.
  35. Asbury AK, Aldredge H, Hershberg R, Fisher CM. Oculomotor palsy in diabetes mellitus: a clinico-pathological study. *Brain* 1970;93:555–66.
  36. Jung JS. Risk factors and prognosis of isolated ischemic third, fourth, or sixth cranial nerve palsies in the Korean population. *J Neuroophthalmol* 2015;35:37–40.
  37. Jeong JS, Kim DH. Associated injuries and prognosis in traumatic isolated 3<sup>rd</sup>, 4<sup>th</sup>, and 6<sup>th</sup> cranial nerve palsies. *J Korean Ophthalmol Soc* 2014;55:596–601.
  38. Chen H, Wang X, Yao S, Raza HK, Jing J, Cui G. The aetiologies of unilateral oculomotor nerve palsy: a clinical analysis on 121 patients. *Somatosens Mot Res* 2019;36:102–8.