

# Concomitant Hyperparathyroidism Due to Occult Parathyroid Adenoma Detected by Technetium-99m Sestamibi Single-photon Computed Tomography/Computerized Tomography in a Patient with Papillary Thyroid Carcinoma

Jiraporn Sriprapaporn, M.D.<sup>1</sup>, Pongthep Pisarnturakit, M.D.<sup>2</sup>, Tauangtham Anekpuritanang, M.D.<sup>3</sup>

<sup>1</sup>Department of Radiology, Faculty of Medicine Siriraj Hospital, Mahidol University, Bangkok Noi, Bangkok 10700, Thailand.

<sup>2</sup>Department of Surgery, Faculty of Medicine Siriraj Hospital, Mahidol University, Bangkok Noi, Bangkok 10700, Thailand.

<sup>3</sup>Department of Pathology, Faculty of Medicine Siriraj Hospital, Mahidol University, Bangkok Noi, Bangkok 10700, Thailand.

Received 22 February 2020 • Revised 14 April 2020 • Accepted 21 April 2020 • Published online 3 July 2020

## Abstract:

Although the occurrence of thyroid and parathyroid diseases is common, concomitant parathyroid adenoma and papillary thyroid carcinoma is rare. We report the case of a 77-year-old Thai woman who was diagnosed to have papillary thyroid carcinoma and postoperative hypercalcemia. The primary hyperparathyroidism was initially overlooked but was subsequently confirmed to be due to a single occult parathyroid adenoma demonstrated on technetium-99m sestamibi (Tc-99m MIBI) parathyroid scintigraphy. Thus, preoperative evaluation of parathyroid disease should be performed if there is evidence of hypercalcemia prior to the thyroid surgery. Presurgical evaluation with Tc-99m MIBI parathyroid single-photon computed tomography/computerized tomography imaging has a definite role in localizing a hyperfunctioning parathyroid gland in the cases of primary hyperparathyroidism.

**Keywords:** hyperparathyroidism, parathyroid adenoma, parathyroid scintigraphy, SPECT/CT, thyroid cancer

**Contact:** Assoc. Prof. Jiraporn Sriprapaporn, M.D.  
Department of Radiology, Faculty of Medicine Siriraj Hospital, Mahidol University,  
Bangkok Noi, Bangkok 10700, Thailand.  
E-mail: jiraporn.spp@mahidol.ac.th

J Health Sci Med Res 2020;.....  
doi: 10.31584/jhsmr.2020751  
www.jhsmr.org

© 2020 JHSMR. Hosting by Prince of Songkla University. All rights reserved.  
This is an open access article under the CC BY-NC-ND license  
(<http://www.jhsmr.org/index.php/jhsmr/about/editorialPolicies#openAccessPolicy>).

## Introduction

Hyperparathyroidism is the third most common clinical endocrine disorder after diabetes and thyroid disease, with prevalence between 0.1–1.0%.<sup>1–3</sup> Hyperparathyroidism is classified into primary, secondary, and tertiary hyperparathyroidism. Among these, primary hyperparathyroidism is the most common cause of hypercalcemia, which is caused by overactivity of one or more parathyroid glands resulting in excessive release of parathyroid hormone (PTH) leading to elevated serum calcium and low serum phosphate levels.<sup>4,5</sup> The vast majority of primary hyperparathyroidism cases (90.0–95.0%) are sporadic and attributable to a solitary parathyroid adenoma in about 80.0–85.0%, double adenoma in up to 4.0%, and four-gland hyperplasia in the remaining 10.0–15.0% of the cases.<sup>2</sup> Parathyroid carcinoma is a very rare cause of primary hyperparathyroidism, accounting for less than 1.0% of cases.<sup>3</sup>

Among patients undergoing surgery for hyperparathyroidism, a coexisting thyroid disease is quite common, with prevalence greater than 20.0% of the cases, of which benign thyroid diseases are much more common than thyroid cancer.<sup>6</sup> Medullary thyroid cancer may be associated with hyperparathyroidism in a hereditary syndrome, called multiple endocrine neoplasia 2A (MEN2A) but a concomitant non-medullary thyroid cancer such as papillary thyroid cancer and hyperparathyroidism are not genetically related and have been reported in the range of 2.0% to 7.0% of patients with primary hyperparathyroidism.<sup>7,8</sup>

The occurrence of primary hyperparathyroidism in a patient with non-medullary thyroid cancer is extremely rare.<sup>6,8</sup> Although there have been several reports about the coexisting of thyroid diseases and hyperparathyroidism, the etiology of this combination remains unclear.<sup>6</sup>

We present here the case of a 77-year-old woman who was first diagnosed as papillary thyroid carcinoma and treated with total thyroidectomy and radioactive iodine ablation, with subsequent detection of a hyperfunctioning parathyroid gland by technetium-99m sestamibi (Tc-99m MIBI) parathyroid single-photon computed tomography/computerized tomography (SPECT/CT) imaging. Parathyroid adenoma was pathologically confirmed after surgery.

## Case report

A 77-year-old woman was diagnosed as papillary thyroid cancer and treated with total thyroidectomy and I-131 ablation. Two days postoperatively, she had initial serum total calcium measured to be 10.6 milligrams/deciliter (mg/dL) (reference 8.6–10.0 mg/dL) while she was receiving calcium supplementation. Although the dosage of calcium was gradually reduced, the serum total calcium levels remained high, between 10.2 mg/dL and 11.8 mg/dL. After the calcium was discontinued, the serum total calcium and phosphate levels were reevaluated and the serum calcium was still high at 11.5 mg/dL while the serum phosphate was low at 1.9 mg/dL (reference 2.7–4.5 mg/dL). The initial parathyroid hormone level was found to be elevated at 162.2 picograms/milliliter (pg/mL) (reference 15–65 pg/mL), and thus primary hyperparathyroidism was confidently diagnosed 11 months after her thyroid surgery.

Since her diagnostic I-131 whole-body scan and stimulated thyroglobulin level obtained 10 months after radioiodine ablation were negative and ultrasonography did not find any significantly sized cervical lymph nodes, she was classified as an excellent response according to the 2015 American Thyroid Association guideline.<sup>9</sup>

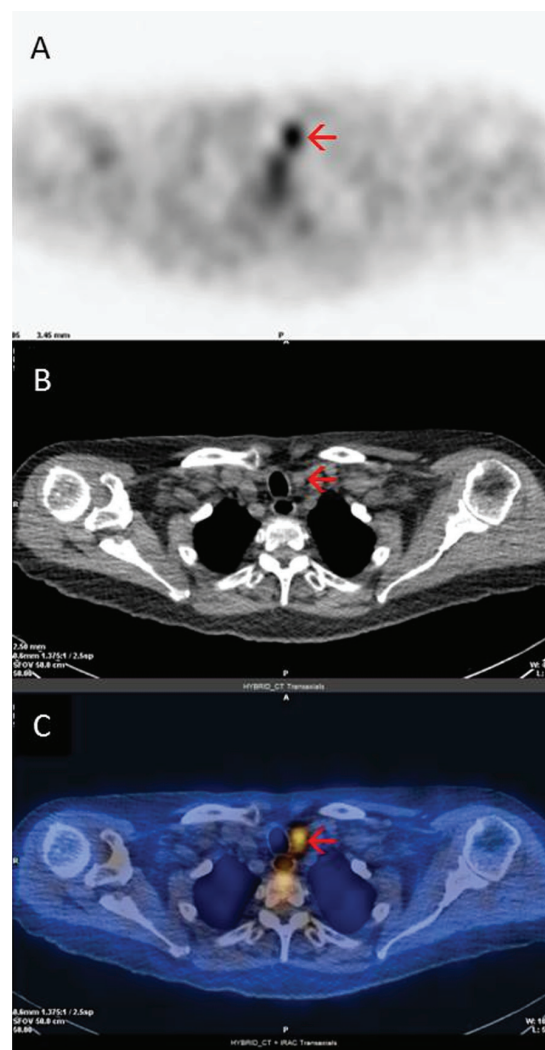
Later, she was scheduled for preoperative localization of the hyper-functioning parathyroid gland to

facilitate minimally invasive parathyroid surgery by parathyroid scintigraphy, which is currently the most popular imaging modality used in cases of primary hyperparathyroidism.

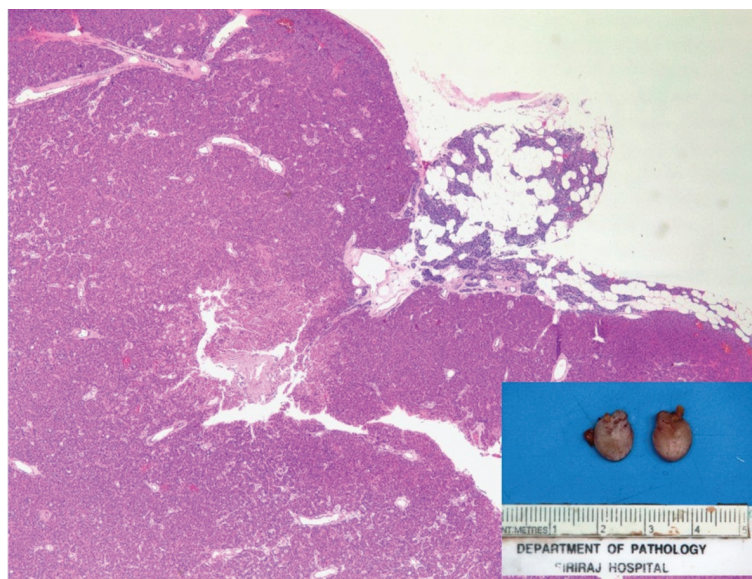
The parathyroid scintigraphy was performed on a Discovery NM/CT 670 (GE Healthcare) using technetium-99m methoxy isobutyl isonitrile (Tc-99m sestamibi or Tc-99m MIBI). A dual-phase technique was used for planar static images of the neck and the chest at 10 minutes (early images) and 3 hours (delayed images) following intravenous administration of 740 megabecquerels or 20 millicuries of Tc-99m sestamibi. In addition, low-dose, non-contrast SPECT/CT imaging was also performed after the early images had been completed. The early and delayed planar Tc-99m sestamibi images showed mild focal radiotracer accumulation at the left side of the neck with delayed washout on the delayed image.

Additional SPECT/CT images revealed focal increased radiotracer uptake at the lower part of the left thyroid bed region with an associated small soft tissue lesion, measuring about 0.9 centimeters (cm) in diameter, at which time a parathyroid adenoma was considered (Figure 1).

Since surgery is the definitive treatment for primary hyperparathyroidism, she was subsequently operated on and an abnormal left lower parathyroid gland was removed. The removed parathyroid gland measured 1.1x0.8x0.4 cm in size and weighed 260 mg. The histopathologic findings were compatible with a parathyroid adenoma (Figure 2). After successful surgery, the levels of serum PTH and serum calcium were normalized. The patient had remained asymptomatic throughout the entire course of the disease.



**Figure 1** Technetium-99m sestamibi parathyroid single-photon emission computed tomography/computerized tomography revealing focal increased radiotracer uptake at the lower part of the left thyroid bed region with an associated small soft tissue lesion, measuring about 0.9 cm in diameter (arrow), which was compatible with a hyperfunctioning parathyroid gland. (A) single-photon emission computed tomography image, (B) computed tomography image, (C) Fused single-photon emission computed tomography/computerized tomography image



**Figure 2** Specimen photograph (inset) and photomicrograph of the removed parathyroid gland demonstrating monotonous nodular proliferation of oxyphil cells with small atrophic non-neoplastic parathyroid residue at the upper right corner, the diagnostic features of a parathyroid adenoma.

## Discussion

In general, benign thyroid diseases are quite common in patients with primary hyperparathyroidism, but non-medullary thyroid cancer has been reported in only 2.0% to 7.0% of these patients, of which the most common is papillary carcinoma. However, the occurrence of primary hyperparathyroidism in a patient with non-medullary thyroid cancer is extremely rare.<sup>6,8</sup>

Most of the published papers to date have reported on the prevalence of hyperparathyroidism in patients undergoing thyroid surgeries but few have reported on the prevalence of coexisting thyroid cancer and hyperparathyroidism in these groups of patients.

Wright et al.<sup>8</sup> reviewed 400 patients undergoing thyroidectomies and discovered 149 thyroid cancers. Only 43 (10.8%) were found to have coexisting parathyroid disease. None in the thyroid cancer group had synchronous parathyroid lesions.

In another report by Ghorra et al.<sup>10</sup>, among 253 out of 1,277 thyroidectomized patients who were confirmed to have thyroid cancer, only 9 cases had concomitant non-medullary thyroid cancer and parathyroid lesions – in other words, only 9 out of 1,277 (0.7%) thyroid surgeries found coexisting thyroid cancer and parathyroid pathology.

In a larger series from Jovanovic et al.<sup>6</sup>, a review of a database of 4,882 patients undergoing thyroid and parathyroid surgeries found 849 patients primarily operated on due to primary hyperparathyroidism and 4,033 cases primarily operated on due to thyroid disorders. Among the primary hyperparathyroidism patients, 224 out of the 849 (26.4%) had coexisting thyroid gland diseases that required surgery, while only 114 out of the 4,033 (2.8%) patients with thyroid diseases had a parathyroidectomy done at the same time. In the latter group, only 21 patients had non-medullary thyroid cancer, of which papillary carcinoma was the most common. Thus, the prevalence of

coexisting non-medullary thyroid cancer and parathyroid disease was only 0.5% in this thyroidectomized group.

The majority of primary hyperparathyroidism cases are sporadic in origin and only a minority are genetically related, such as MEN1 and MEN2A. In addition, few of the reported cases since the first published case report in 1975 had a history of prior head and neck irradiation or history of radioactive iodine treatment, and most of them occurred after treatment for benign thyroid diseases with a long mean latency period of  $13.5 \pm 9.1$  years.<sup>11,12</sup> Thus, this etiology was unlikely for our patient.

Although Tc-99m MIBI is a non-specific tumor agent that can be positive in thyroid and parathyroid tumors as well as other types of tumors, abnormal radiotracer accumulation at the thyroid bed with an associated negative I-131 whole-body scan and undetectable thyroglobulin level makes it less likely to be related to residual thyroid cancer or metastatic lymph nodes. In this context with a high serum PTH level, focal uptake of Tc-99m MIBI would suggest a hyperfunctioning parathyroid lesion rather than a thyroid cancer etiology. There have been several case reports regarding this rare phenomenon but only a few studies demonstrating the advantage of using Tc-99m MIBI parathyroid SPECT/CT.<sup>13,14</sup>

In a meta-analysis of 18 studies in patients with primary hyperparathyroidism, Wei et al. reported that dual-phase sestamibi SPECT/CT was far more sensitive and accurate than planar scintigraphy with a pooled sensitivity of 84.0% over 63.0% and a pooled PPV of 95.0% over 90.0%.<sup>15</sup>

In general, Tc-99m MIBI parathyroid scintigraphy can detect parathyroid adenomas greater than 500 mg with high sensitivity.<sup>16</sup> By using a modern scanner, parathyroid lesions as small as 100–150 mg can be detected.<sup>16</sup> With SPECT acquisition, Calva-Cerqueira et al.<sup>18</sup> found that the parathyroid gland weight threshold of 250 mg could

provide a high sensitivity of 85.0%. In addition, when Tc-99m MIBI SPECT/CT was used, Kim et al.<sup>19</sup> reported that the smallest parathyroid lesion that could be detected had a diameter of only 0.8 cm with a 3D volume of 0.2 cm<sup>3</sup>.

In our current case, Tc-99m sestamibi parathyroid scintigraphy was very helpful in localizing the hyperfunctioning parathyroid gland even though the gland was rather small, only 1.1x0.8x0.4 cm in size and 260 mg in weight, which indicates that this technique is highly sensitive for detection of an abnormal parathyroid lesion.

## Conclusion

Since hyperparathyroidism may occur in patients with thyroid diseases, complete preoperative evaluation of serum calcium and the subsequent parathyroid hormone level should be obtained if there is any evidence of hypercalcemia to ensure a single thyroid and parathyroid operation at the same time if required and thus preventing unnecessary reoperations. Our study offers strong evidence that preoperative imaging localization with dual-phase Tc-99m sestamibi parathyroid SPECT/CT is highly sensitive even in a small hyperfunctioning parathyroid gland.

## Funding sources

This manuscript was supported by a Chalermprakiat Grant from the Faculty of Medicine Siriraj Hospital, Mahidol University, Thailand.

## Conflict of interest

The authors declare no conflicts of interest.

## References

1. Rao SD. Epidemiology of parathyroid disorders. *Best Pract Res Clin Endocrinol Metab* 2018;32:773–80.
2. Cordellat IM. Hyperparathyroidism: primary or secondary disease? *Rheumatol Clin* 2012;8:287–91.



3. Gopinath P, Mihai R. Hyperparathyroidism. *Surgery* 2011;29:451–8.
4. Shindo M, Lee JA, Lubitz CC, McCoy KL, Orloff LA, Tufano RP, et al. The changing landscape of primary, secondary, and tertiary hyperparathyroidism: highlights from the American College of Surgeons panel, “What's new for the surgeon caring for patients with hyperparathyroidism?”. *J Am Coll Surg* 2016;222:1240–50.
5. Madkhali T, Alhefdhi A, Chen H, Elfenbein D. Primary hyperparathyroidism. *Ulus Cerrahi Derg* 2016;32:58–66.
6. Jovanovic MD, Zivaljevic VR, Diklic AD, Rovcanin BR, V Zoric G, Paunovic IR. Surgical treatment of concomitant thyroid and parathyroid disorders: analysis of 4882 cases. *Eur Arch Otorhinolaryngol* 2017;274:997–1004.
7. Bentrem DJ, Angelos P, Talamonti MS, Nayar R. Is preoperative investigation of the thyroid justified in patients undergoing parathyroidectomy for hyperparathyroidism? *Thyroid* 2002;12:1109–12.
8. Wright MC, Jensen K, Mohamed H, Drake C, Mohsin K, Monlezun D, et al. Concomitant thyroid disease and primary hyperparathyroidism in patients undergoing parathyroidectomy or thyroidectomy. *Gland Surg* 2017;6:368–74.
9. Haugen BR, Alexander EK, Bible KC, Doherty GM, Mandel SJ, Nikiforov YE, et al. 2015 American Thyroid Association Management Guidelines for Adult Patients with Thyroid Nodules and Differentiated Thyroid Cancer: The American Thyroid Association Guidelines Task Force on Thyroid Nodules and Differentiated Thyroid Cancer. *Thyroid* 2016;26:1–133.
10. Ghorra C, Rizk H, Abi Hachem R, Tannoury J, Abboud B. Association of parathyroid pathology with well-differentiated thyroid carcinoma. *Presse Med* 2012;41:e265–71.
11. Rosen IB, Strawbridge HG, Bain J. A case of hyperparathyroidism associated with radiation to the head and neck area. *Cancer* 1975;36:1111–4.
12. Colaço SM, Si M, Reiff E, Clark OH. Hyperparathyroidism after radioactive iodine therapy. *Am J Surg* 2007;194:323–7.
13. Cadena-Piñeros E, De Los Reyes CA, Llamas-Olier A, Romero-Rojas AE. Advantages of the (99m)Tc-sestamibi Single-Photon Emission Computed Tomography/Computed Tomography in Occult Parathyroid Adenoma and Concomitant Thyroid Papillary Carcinoma. *Indian J Nucl Med* 2019;34:150–2.
14. Taywade SK, Damle NA, Tripathi M, Agarwal S, Aggarwal S. Synchronous parathyroid adenoma and papillary thyroid cancer detected on 99mTc-sestamibi scintigraphy. *Indian J Endocrinol Metab* 2016;20:878–9.
15. Wei WJ, Shen CT, Song HJ, Qiu ZL, Luo QY. Comparison of SPET/CT, SPET and planar imaging using 99mTc-MIBI as independent techniques to support minimally invasive parathyroidectomy in primary hyperparathyroidism: a meta-analysis. *Hell J Nucl Med* 2015;18:127–35.
16. Norton KS, Johnson LW, Griffen FD, Burke J, Kennedy S, Aultman D, et al. The sestamibi scan as a preoperative screening tool. *Am Surg* 2002;68:812–5.
17. Efstratios Moravidis. Radionuclide parathyroid imaging: a concise, updated review *Hell J Nucl Med* 2013;16:125–33.
18. Calva-Cerqueira D, Smith BJ, Hostetler ML, Lal G, Menda Y, O'Dorisio TM, et al. Minimally invasive parathyroidectomy and preoperative MIBI scans: correlation of gland weight and preoperative PTH. *J Am Coll Surg* 2007;205(Suppl 4):S38–44.
19. Kim YI, Jung YH, Hwang KT, Lee HY. Efficacy of <sup>99m</sup>Tc-sestamibi SPECT/CT for minimally invasive parathyroidectomy: comparative study with <sup>99m</sup>Tc-sestamibi scintigraphy, SPECT, US and CT. *Ann Nucl Med* 2012;26:804–10.