

Success Rate of Drilling and Knuckle Wire Crossing Technique in Chronic total Occlusion of the Femoro–Popliteal Artery and Predicting Factors Related to it in Real–World Data

Sorracha Rookkapan, M.D.¹, Thanakorn Phothong, M.D.¹, Keerati Hongsakul, M.D.¹, Jitpreedee Sungsi, M.D.¹, Surasit Akkakissee, M.D.¹, Phurich Janjindamai, M.D.¹, Boonprasit Kritpracha, M.D.², Wittawat Tantarattanapong, M.D.², Pong Juntarapatin, M.D.², Supong Worathanmanon, M.D.²

¹Division of Body Interventional Radiology, Department of Radiology, Faculty of Medicine, Prince of Songkla University, Hat Yai, Songkhla 90110, Thailand.

²Division of Vascular Surgery, Department of Surgery, Faculty of Medicine, Prince of Songkla University, Hat Yai, Songkhla 90110, Thailand.

Received 6 May 2024 • Revised 3 July 2024 • Accepted 5 July 2024 • Published online 21 October 2024

Abstract:

Objective: Crossing chronic total occlusion (CTO) in femoro–popliteal (FP) arteries is challenging. Hence, this study aimed to describe real-world data on the technical success rate of crossing FP CTO lesions, and analyze predicting factors for crossing failure.

Material and Methods: This retrospective study, conducted at a single center, involved patients with peripheral arterial disease (PAD) and FP CTOs, categorized as Rutherford categories 3–6, having undergone endovascular recanalization from 2017 to 2022. Baseline characteristics and crossing success rates were described using frequencies, percentages, means, medians, standard deviations, and interquartile ranges. Factors associated with crossing failure were analyzed through logistic regression analysis, with statistical significance set at a p-value<0.05.

Results: Among the 181 patients analyzed, the majority exhibited minor tissue loss (63%) and severe disease (TASC II category D, GLASS grade 4). The predominant CTO crossing approach was based on plaque cap morphology (CTOP) classification type B (66.9%), with severe CTO calcification (PACSS type 4) in 23.8%. Median occlusion length was 16.1 cm; 85.6% successfully crossed the CTO and antegrade success was 57.5%. Factors associated with crossing failure

Contact: Sorracha Rookkapan, M.D.
Division of Body Interventional Radiology, Department of Radiology, Faculty of Medicine,
Prince of Songkla University, Hat Yai, Songkhla 90110, Thailand.
E-mail: srookkapan@gmail.com

J Health Sci Med Res
doi: 10.31584/jhsmr.20241104
www.jhsmr.org

© 2024 JHSMR. Hosted by Prince of Songkla University. All rights reserved.
This is an open access article under the CC BY–NC–ND license
(<http://www.jhsmr.org/index.php/jhsmr/about/editorialPolicies#openAccessPolicy>).

included: CTO types C or D, CTO at the P3–popliteal artery, severe CTO calcification, and dyslipidemia. Retrograde recanalization showed higher success rates in CTO type D and longer occlusions.

Conclusion: This study highlights the safety and effectiveness of the catheter–wire crossing technique for FP CTOs. CTO classification, CTO location, severe calcification, and dyslipidemia predicted crossing failure. The retrograde approach works well in CTO type D and longer CTOs, providing insights for improving success in clinical practice.

Keywords: chronic limb–threatening ischemia, chronic total occlusion, crossing the lesion, femoro–popliteal arteries, predictive factor

Introduction

Peripheral arterial disease (PAD) is a prevalent form of atherosclerosis, affecting over a hundred million individuals worldwide and significantly reduces their quality of life^{1,2}. Chronic total occlusion (CTO) in the femoro–popliteal (FP) segment is common in PAD cases comprising more than half^{1,3}. Although, both endovascular revascularization and open surgery are treatment options for FP lesions, this minimally invasive endovascular treatment has led to extensive investigation and promising outcomes¹.

The success of endovascular interventions crucially depends on the ability to navigate the lesion^{1,4}. However, crossing CTO lesions remains a significant, technical challenge, with reported failure rates of up to 30% in complex cases. Failure to cross CTO lesions may hinder treatment, potentially prolonging procedural time, increasing costs, and increasing the risk of limb amputation^{3,5–8}. Previous studies have identified factors predicting failure in crossing CTO; including characteristics; such as degree of calcification, length, location and morphology^{3,5,9–11}. Novel procedural techniques; like subintimal recanalization, subintimal arterial flossing with antegrade–retrograde intervention (SAFARI), controlled antegrade and retrograde tracking (CART) have been developed to overcome these challenges^{12–15}. Retrograde recanalization has demonstrated effectiveness in traversing specific chronic CTO morphologies^{4,5,8,16}.

The introduction of the CTO crosser device aimed to streamline the process of CTO crossing, with studies demonstrating its effectiveness in improving technical success rates^{1,17}. However, these advanced recanalization techniques and tools have limitations. For example, subintimal recanalization may encounter reentry failure in up to 27% of cases¹⁸, while retrograde recanalization may encounter obstacles in cases where distal runoff vessels are compromised⁸. Additionally, the availability of the CTO crosser device is currently restricted to specific regions, potentially leading to increased procedural costs¹⁹.

Despite advancements, reported technical success rates for crossing FP CTO lesions using only catheter–wire techniques remain limited. Therefore, our aim is to present real–world data on the technical success rate of crossing FP CTO lesions and to analyze predicting factors for crossing failure.

Material and Methods

Population

This single–center retrospective observational descriptive study, approved by the institutional ethics committee, focuses on patients diagnosed with PAD, presenting with severe intermittent claudication, ischemic rest pain, minor tissue loss–nonhealing ulcer or major tissue loss or gangrene of the foot (Rutherford classification 3–6)²⁰.

Specifically, it encompasses individuals with de novo CTO lesions or re-occlusion of CTO lesions at the FP artery having undergone endovascular revascularization treatment at a university hospital in Southern Thailand; from January 2017 to December 2022. Exclusion criteria pertained to patients with vascular trauma, a history of bypass grafts, or in-stent re-occlusion within the FP artery.

Data collection

Data were retrieved from medical records, and a vascular interventional radiologist specializing in peripheral arterial intervention meticulously evaluated clinical information, angiographic images, procedure reports, and outcomes. Lesion characteristics. This also included length, which was meticulously assessed for the CTO crossing approach as per plaque cap morphology (CTOP) classification⁵, and calcium severity. This was according to the peripheral arterial calcium scoring system (PACSS)²¹, which was determined through intraoperative digital subtraction angiography conducted alongside the endovascular recanalization procedure. The morphology of the proximal superficial femoral artery CTO stump was categorized as tapered or flush occlusion, and any combined arterial occlusion at the iliac and below-the-knee levels was meticulously recorded.

Procedure technique

The procedures were performed by two qualified interventional radiologists: 92% of cases by an interventional radiologist with 17 years of experience and 8% by an interventional radiologist with 15 years of experience in PAD procedures. CTO recanalization involved a stepwise wire-catheter-based approach, preceded by dual antiplatelet therapy and intraprocedural heparinization. Patients received an initial intra-arterial dose of 5,000 IU heparin, followed

by 1,000 IU hourly. Antegrade recanalization served as the preferred initial approach. A range of workhorse guidewires (e.g., V-18TM Control WireTM, Boston Scientific, Marlborough, MA, USA and Command ES Guide Wire, Abbott Vascular, Santa Clara, CA, USA) and CTO-specific guidewires (e.g., VictoryTM 18, Boston Scientific, Marlborough, MA, USA and Astato[®] 30 or Astato[®] 40, ASAHI Intecc CO., LTD, Aichi, Japan) were utilized alongside supporting catheters. Typically, the workhorse guidewire was employed first; if unsuccessful, the CTO-specific guidewire was then utilized. In cases where antegrade crossing failed after being attempted at least 15 minutes with a workhorse and CTO guide wire but patent distal arterial access was available, retrograde recanalizations were performed under ultrasound guidance, with the V-18TM Control WireTM initially employed. Following the successful retrograde crossing of the CTO, the guidewire was externalized via an antegrade catheter through the vascular sheath. Subsequently, hemostasis of the distal access site was achieved using a low-pressure balloon and external compression, followed by lesion treatment from the antegrade approach. The selection of vascular sheaths was based on the treatment applied and vascular access site, with a 6Fr vascular sheath initially used in most cases at the common femoral artery. No re-entry or crosser devices were utilized. The choice of devices, retrograde access site, and crossing strategies were determined at the vascular interventionalist's discretion.

Definition

PAD is defined as chronic limb ischemia presenting with the clinical presentations as: claudication; Rutherford's classification 1-3, and critical limb threatened ischemia (CLTI); ischemic rest pain, minor tissue loss-nonhealing ulcers, or major tissue loss or gangrene of the foot (Rutherford's classification 4-6)²⁰.

Crossing success was defined as the ability to advance the guidewire beyond the opposite side of the CTO cap into its true lumen: confirmed by angiography. Secondly, guidewire escalation or crossing techniques for the procedure included a drilling wire, knuckle wire, or combined techniques²². In complex cases, techniques; such as SAFARI, CART and reverse CART were employed.

CTO refers to the complete occlusion of an arterial segment observed through imaging presenting as PAD symptoms persisting for at least 3 months. The CTOP classification system⁵ was employed to characterize CTO cap morphology, based on angiographic findings; delineating four types: type 1 exhibits concave proximal and distal caps, type 2 displays concave proximal and convex distal caps, type 3 features convex proximal and concave distal caps, and type 4 presents with convex proximal and distal caps. Additionally, the PACSS²¹ was utilized to evaluate the extent of arterial wall calcification at the CTO site, with five grades being described: grade 0 shows no visible calcification. Grade 1 indicates unilateral wall calcification <5 cm in length, and grade 2 if ≥5 cm in length. Grade 3 represents bilateral wall calcification <5 cm in length, and grade 4 if ≥5 cm in length. Severe calcification being PACSS grade 4.

Statistical analysis

Statistical analysis and graphical representations were conducted using the Epicalc package (version 3.1.1.2, Songkhla, Thailand, 2016) in conjunction with R program version 3.2.2 (R Foundation for Statistical Computing, Vienna, Austria, 2016). Categorical data was presented as percentages, with continuous data expressed as mean and standard deviation, and non-parametric data was presented as median and interquartile range. Factors associated with CTO crossing failure were analyzed through univariable analysis, utilizing the chi-square test or Fisher's exact test for categorical data and the Wilcoxon rank-sum test for

continuous data. Multivariate analysis was performed using stepwise logistic regression, incorporating variables that achieved a p-value < 0.2 in the univariate model. Results are reported as odds ratio with a 95% confidence interval. A p-value < 0.05 was considered statistically significant.

Results

Baseline characteristic

In our study of 181 patients, the median age was 69 years, most were male (69.6%), and the majority had minor tissue loss (63.0%, Rutherford class 5). PAD lesions were severe, at 68.5%; falling into TASC II category D and GLASS grade four for the FP segment. CTOP type B was prevalent (66.9%), with nearly equal distribution between CTO lesions with and without calcification (55.2% versus 44.8%). The median occlusion length was 16.1 cm. CTO lesions were most common in the distal SFA (66.9%). Pre- and post-treatment ankle-brachial index measurements showed significant improvement (mean ABI improvement: 0.37 ± 0.2). Tables 1–3 offer a detailed summary of patient demographics, lesion characteristics, and procedural details.

Crossing CTO Lesions

Out of 181 patients, 155 (85.6%) had successfully crossed CTO lesions. The antegrade approach succeeded in 57.5% of cases, with 76 using a workhorse guidewire and 28 requiring a specialized CTO guidewire. Following unsuccessful antegrade crossing, the retrograde approach was attempted in 64 out of 77 patients, resulting in successful crossing in 79.7% of cases. Most retrograde crossings were achieved using a 0.018 workhorse guidewire (90.2%). Retrograde access primarily targeted the popliteal artery (50.0%); other routes included: the distal SFA (29.7%), distal posterior tibial artery (14.0%), and dorsalis pedis artery (6.3%).

For the successful crossing group, various guidewire passing techniques were employed; including drilling (56.1%), knuckle (38.7%), and combined techniques (5.2%). The intraluminal passage was observed in 56.8% of cases, while subintimal passage occurred in 43.2%. Advanced techniques; such as SAFARI, were utilized in 20% of cases, and the reverse CART technique in 3.9%.

Table 1 Baseline demographic of patients stratified by successful crossing of CTO lesions

Variable	Total	Success crossing group (155 patients)	Failure crossing group (26 patients)	p-value
Age, years, median (IQR)	69 (61.0, 77.0)	68 (60.0, 76.0)	72.5 (64.2, 80.8)	0.126
Gender, male (%)	126 (69.6)	109 (70.3)	17 (65.4)	0.782
Risk factors (%)				
Hypertension	138 (76.2)	116 (74.8)	22 (84.8)	0.404
Diabetes mellitus	99 (54.7)	87 (56.1)	12 (46.2)	0.464
Dyslipidemia	79 (43.6)	62 (40.0)	17 (65.4)	0.028*
Chronic kidney disease	35 (19.3)	29 (18.7)	6 (23.1)	0.8
End-stage renal disease	16 (8.8)	13 (8.4)	3 (11.5)	0.706
Coronary artery disease	50 (27.6)	39 (25.2)	11 (42.3)	0.116
Active smoker	65 (35.4)	56 (36.1)	8 (30.8)	0.759
Current medication (%)				
Statin	153 (84.5)	133 (85.8)	20 (76.9)	0.248
Aspirin	154 (85.1)	131 (84.5)	23 (88.5)	0.771
Dual antiplatelet	31 (17.1)	25 (16.1)	6 (23.1)	0.402
Cilostazol	96 (53.0)	81 (52.3)	15 (57.7)	0.763
Anticoagulant	12 (6.6)	9 (5.8)	3 (11.5)	0.384
Rutherford classification (%)				0.696
Class 3	23 (12.7)	21 (13.5)	2 (7.7)	
Class 4	19 (10.5)	15 (9.7)	4 (15.4)	
Class 5	114 (63.0)	98 (63.2)	16 (61.5)	
Class 6	25 (13.8)	21 (13.5)	994 (15.4)	
ABI				
Pre-treatment ABI, median (IQR)	0.5 (0.3, 0.6)	0.5 (0.4, 0.6)	0.4 (0.3, 0.6)	0.496
Post-treatment ABI, median (IQR)	0.9 (0.7, 1.1)	0.9 (0.7, 1.1)	NA	NA
ABI improvement, mean (S.D.)	0.4 (0.2)	0.4 (0.2)	NA	NA

*presence of significant difference

ABI=ankle-brachial index, IQR=interquartile range, S.D.=standard deviation, NA=not available

Table 2 Lesion characteristics stratified by successful crossing of the CTO lesion

Variable	Total	Success crossing group (155 patients)	Failure crossing group (26 patients)	p-value
TASC classification (%)				0.023*
A	4 (2.2)	4 (2.6)	0 (0)	
B	9 (5.0)	7 (4.5)	2 (7.7)	
C	44 (24.3)	43 (27.7)	1 (3.8)	
D	124 (68.5)	101 (65.2)	23 (88.5)	
GLASS grading (%)				0.111
1	6 (3.3)	6 (3.9)	0 (0)	
2	19 (10.5)	17 (11.0)	2 (7.7)	
3	32 (17.7)	31 (20.0)	1 (3.8)	
4	124 (68.5)	101 (65.2)	23 (88.5)	
CTOP classification (%)				0.02*
A	19 (10.5)	17 (11.0)	2 (7.7)	
B	121 (66.9)	109 (70.3)	12 (46.2)	
C	6 (3.3)	4 (2.6)	2 (7.7)	
D	35 (19.3)	25 (16.1)	10 (38.5)	
Calcification severity (%)				0.098
Non-severe calcification	138 (76.2)	122 (78.7)	16 (61.5)	
Severe calcification	43 (23.8)	33 (21.3)	10 (38.5)	
Occlusion length (%)				0.038*
<10 cm	69 (38.1)	64 (41.3)	5 (19.2)	
10–20 cm	34 (18.8)	30 (19.4)	4 (15.4)	
>20 cm	78 (43.1)	61 (39.4)	17 (65.4)	
Length, cm, median (IQR)	16.1 (7.3, 27.2)	14.5 (6.4, 25.9)	26.7 (11.1, 34.4)	0.002*
CTO location (%)				
Proximal SFA	84 (46.4)	68 (43.9)	16 (61.5)	0.145
Mid SFA	111 (61.3)	92 (59.4)	19 (73.1)	0.266
Distal SFA	121 (66.9)	101 (65.2)	20 (76.9)	0.34
P1-PA	44 (24.3)	38 (24.5)	6 (23.1)	1
P2-PA	50 (27.6)	41 (26.5)	9 (34.6)	0.532
P3-PA	41 (22.7)	32 (20.6)	9 (34.6)	0.186
Flush occlusion at proximal SFA (%)	27 (32.1)	20 (29.4)	7 (43.8)	0.419
Tapered occlusion at proximal SFA (%)	25 (29.8)	21 (30.9)	4 (25.0)	0.767
Combined iliac inflow CTO (%)	34 (18.8)	26 (16.8)	8 (30.8)	0.105

Table 2 (continued)

Variable	Total	Success crossing group (155 patients)	Failure crossing group (26 patients)	p-value
Combined below the knee CTO (%)	153 (84.5)	132 (85.2)	21 (80.8)	0.562
Combined iliac and below the knee CTO (%)	28 (15.5)	22 (14.2)	6 (23.1)	0.248

*presence of significant difference

TASC=the TransAtlantic Inter-Society Consensus, GLASS=the Global Limb Anatomic Staging System, CTOP=crossing approach: based on plaque cap morphology, PACSS=the peripheral artery calcification scoring system, CTO=chronic total occlusion, SFA=superficial femoral artery, PA=popliteal artery, IQR=interquartile range

Table 3 Technical characteristic stratified by successful crossing of CTO lesions

Variable	Total	Success crossing group (155 patients)	Failure crossing group (26 patients)	p-value
Vascular access (%)				
Antegrade ipsilateral CFA	34 (18.8)	31 (20.0)	3 (11.5)	0.42
Contralateral CFA crossover	134 (74)	113 (72.9)	21 (80.8)	0.545
Brachial artery	15 (8.3)	13 (8.4)	2 (7.7)	1
Distal retrograde	67 (37)	54 (34.8)	13 (50.0)	0.207

CFA=common femoral artery

Factors associated with FP CTO crossing failure

Factors significantly associated with FP CTO crossing failure were analyzed. In the univariate analysis, older age, underlying dyslipidemia, coronary artery disease, clinical TASC II classification D, GLASS grade 4, CTOP type D morphology, severe CTO calcification, longer occlusion length, and specific lesion locations showed significant associations. In the multivariate analysis four key factors were identified as posing higher risks for crossing failure: underlying dyslipidemia (OR 2.94, 95% CI 1.15–7.51, p-value=0.024), CTOP type C or D (OR 3.77, 95% CI 1.45–9.81, p-value=0.006), CTO lesion at the P3–popliteal

artery (OR 4.6, 95% CI 1.53–13.85, p-value=0.007) and the presence of severe CTO calcification (OR 3.57, 95% CI 1.23–10.66, p-value=0.019). These findings are graphically represented as a forest plot in Figure 1.

Prediction of favoring retrograde recanalization

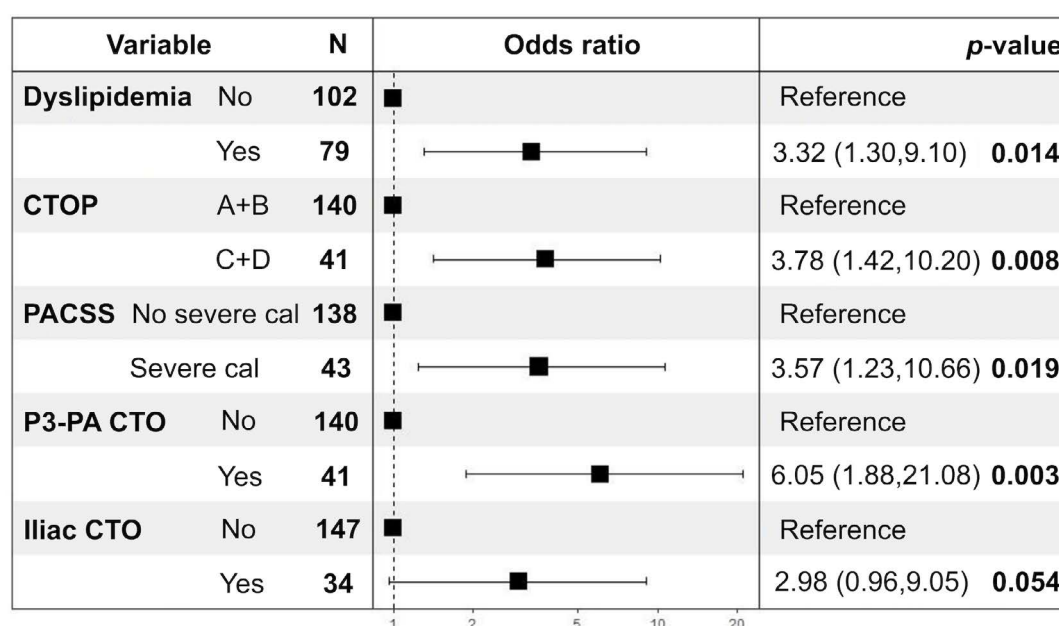
Statistically significant predictors for favoring retrograde recanalization were: CTOP type D (23.5% versus 12.5%, p-value=0.002) and longer occlusion length (median 20.8 cm versus 9.8 cm, p-value<0.001). Notably, no significant differences were found in success rates between antegrade and retrograde approaches regarding clinical presentation,

lesion characteristics, calcification severity, and the presence of flush occlusion. The concise comparison of factors influencing both technical successes are summarized in Table 4.

Complications

The most common vascular access site complication was at 12.2%, for which the most common was non-expanded hematoma (17 patients). One patient had an arteriovenous fistula from the retrograde puncture

site, which did not require any intervention. Vascular perforation happened in 7.7%, which were treated with prolonged balloon inflation, cover stenting, or bare metal stent placement. Additionally, 10 patients had distal emboli managed with heparinization or thrombectomy, and 7 had flow-limiting dissection: often requiring stenting. No procedure-related deaths occurred. Table 5 summarizes the complications encountered.



CTOP=crossing approach based on plaque cap morphology, PACSS=the peripheral artery calcification scoring system, CTO=chronic total occlusion

Figure 1 Forest plot of multivariate analysis; predicting factors associated with CTO crossing failure

Table 4 Clinical and lesion characteristic influencing the success of both antegrade and retrograde recanalization techniques

Variable	Total	Success crossing group (104 patients)	Failure crossing group (51 patients)	p-value
Rutherford classification (%)				0.919
Class 3	21 (13.5)	15 (14.4)	6 (11.8)	
Class 4	15 (9.7)	10 (9.6)	5 (9.8)	
Class 5	98 (63.2)	64 (61.5)	34 (66.7)	
Class 6	21 (13.5)	15 (14.4)	6 (11.8)	

Table 4 (continued)

Variable	Total	Success crossing group (104 patients)	Failure crossing group (51 patients)	p-value
TASC classification (%)				0.962
A	4 (2.6)	3 (2.9)	1 (2.0)	
B	7 (4.5)	5 (4.8)	2 (3.9)	
C	43 (27.7)	30 (28.8)	13 (25.5)	
D	101 (65.2)	66 (63.5)	35 (68.6)	
GLASS grading (%)				0.552
1	6 (3.9)	4 (3.8)	2 (3.9)	
2	17 (11.0)	14 (13.5)	3 (5.9)	
3	31 (20.0)	20 (19.2)	11 (21.6)	
4	101 (65.2)	66 (63.5)	35 (68.6)	
CTOP classification (%)				0.002*
A	17 (11.0)	17 (16.3)	0 (0.0)	
B	109 (70.3)	71 (68.3)	38 (74.5)	
C	4 (2.6)	3 (2.9)	1 (2.0)	
D	25 (16.1)	13 (12.5)	12 (23.5)	
PACSS classification (%)				0.526
0	70 (45.2)	47 (45.2)	23 (45.1)	
1	12 (7.7)	8 (7.7)	4 (7.8)	
2	8 (5.2)	5 (4.8)	3 (5.9)	
3	32 (20.6)	25 (24)	7 (13.7)	
4	33 (21.3)	19 (18.5)	14 (27.5)	
Calcification severity (%)				0.27
Non-severe calcification	122 (78.7)	85 (81.7)	37 (72.5)	
Severe calcification	33 (21.3)	14 (27.5)	19 (18.3)	
Occlusion length (%)				<0.001*
<10 cm	64 (41.3)	54 (51.9)	10 (19.6)	
10–20 cm	30 (19.4)	17 (16.3)	13 (25.5)	
>20 cm	61 (39.4)	33 (31.7)	28 (54.9)	
Length, cm, median (IQR)	14.5 (6.4, 25.9)	9.8 (5, 23.6)	20.8 (11.3, 28.9)	<0.001*
Flush occlusion (%)	20 (29.4)	8 (23.5)	12 (35.3)	0.425

*presence of significant difference

TASC=the TransAtlantic Inter-Society Consensus, GLASS=the Global Limb Anatomic Staging System, CTOP=crossing approach based on plaque cap morphology, PACSS=the peripheral artery calcification scoring system, IQR=interquartile range

Table 5 Complication and severity grading

Complication and treatment	Number	Grade
Groin hematoma	17	2
AVF treated by balloon tamponade and external compression	1	2
Pseudoaneurysm treated by compression	4	3
Vascular perforation treated by	14	3
6 x balloon tamponade		
2 x cover stent		
6 x bare stent		
Distal emboli treated by	10	3
6 x heparinization		
2 x thrombolysis		
2 x thrombectomy		
Flow limiting dissection treated by	7	3
1 x balloon angioplasty		
6 x stenting		

*grading according to CIRSE guideline

AVF=arterio-venous fistula

Discussion

Our study achieved a technical success rate of 85.6% in crossing FP CTO lesions using catheter-wire techniques. This is consistent with the reported success rates in the literature: ranging between 70% and 90%^{3,5,6,8,16,23-25}. However, our success rate was slightly lower than the publication by Wei et al. in 2018²³. This could be due to the study population having presented with more complex diseases, including a higher percentage of CLTI patients, TASC II type D lesions, flush occlusions on proximal SFA, increased CTO calcification involving both vessel walls, and concomitant diseases above SFA –CTO. Both antegrade and retrograde approaches were employed in our study, with the antegrade approach being successful in 57.5% of cases. This success rate was in the range of 37.2% to 82.4%: as reported in the literature^{3,5,7,8,10,23,25}. The proactive use of retrograde recanalization after initial unsuccessful antegrade

attempts contributed to the higher success rate of CTO crossing in 79.7% of cases^{4,6,10}. This highlights the utility of the retrograde approach in overcoming technical challenges and achieving successful recanalization, particularly in cases with complex CTO morphologies, such as flush occlusion, CTOP type D and longer lesions^{5,7,21}.

Factors associated with CTO crossing failure were thoroughly analyzed in our study. Multivariate analysis identified 4 predictors of crossing failure, including the presence of dyslipidemia, CTOP type C or D, CTO lesion at the P3-PA and severe CTO calcification. These findings corroborate previous studies, highlighting the impact of lesion morphology, calcification severity, and patient comorbidities on procedural outcomes^{3,5}. CTOP type C or D presents a convex proximal cap, increasing the risk of deflecting the guidewire into the subintimal space during antegrade attempts. The distal part of the PA CTO consistently

poses a risk for crossing failure due to its distance from the antegrade access site, resulting in reduced pushability and torquability of the guide wire³. Okuno et al.²⁶ established a correlation between PACSS grade 4 and unfavorable outcomes subsequent to endovascular therapy for SFA lesions. As a result, we have subcategorized PACSS grade 4 as indicative of severe calcification^{5,27}. It is widely acknowledged that vascular calcification poses a substantial obstacle to the progression of the guidewire across the lesion. Numerous preceding studies^{3,8,16,21,23,24} have connected severe calcification with the inability to cross CTO lesions, and the results of our study further bolster this correlation.

In univariate analysis, a longer occlusion length showed a significant association with failure to cross CTOs; however, this association did not emerge in multivariate analysis. Notably, previous studies have yielded conflicting results regarding the link between CTO length and crossing failure^{3,24}. Conversely, several studies have underscored that an increased CTO length acts as a risk factor for unsuccessful crossing^{8,10,16,23,25}. Elevated blood lipid levels are known to contribute to atherosclerosis^{28,29}, resulting in luminal narrowing, leading to arterial plaque formation³⁰. Prolonged exposure to plaque can induce arterial remodeling, resulting in luminal narrowing^{29,31}. These factors collectively contribute to increased arterial rigidity and the development of complex occlusions, thereby complicating guidewire navigation. This discovery underscores the imperative of further exploring the association between dyslipidemia and PAD.

Our study also found that the retrograde approach had higher success rates of CTO crossing in CTOP type D as well as longer CTOs compared to the antegrade approach. This is consistent with prior studies^{3,5,8,10,17}. The rationale behind retrograde crossing lies in the relatively less rigid fibrous cap at the distal end compared to the proximal end, facilitating the easier passage of the guidewire⁸. Flush

occlusion did not significantly increase success likelihood with the retrograde approach in our cohort: unlike the findings by Wei et al.²³. However, our study showed similar success rates for crossing flush occlusions from both antegrade and retrograde approaches. Differences in patient characteristics may explain these variations. Despite this, the retrograde approach may still offer advantages in flush occlusion cases, as indicated by a trend toward higher success rates.

Our catheter-wire techniques for FP CTO recanalization showed acceptable complication rates. Distal embolism occurred in 5.5% of cases, flow-limiting dissection in 7%, and vascular perforation in approximately 7.7%. These rates are consistent with literature ranges^{6,8,10,23,31}, with a slightly higher incidence of vascular perforation possibly due to our cohort's complex disease presentations^{6,23,32,33}. Access site complications were reported in 12.2% of cases, aligning with the range recommended by CIRSE standard practice³¹.

Catheter-wire CTO recanalization demonstrates commendable success rates coupled with acceptable complication rates. However, the complex morphology of CTOs, influenced by factors such as cap shape, calcification, location and underlying dyslipidemia, increases procedural failure risk. Specialized crossing devices and techniques may enhance success in such cases. Additionally, the distal retrograde approach offers advantages; especially in specific lesion characteristic, such as CTOs with challenging cap shapes, like CTOP class D and longer occlusion lengths. Comparing our results to other studies reveals advancements in endovascular techniques, including wire technology and imaging modalities, which contributed to improved success rates. However, challenges still persist, particularly in cases with complex morphologies and calcification.

This study provides real-world data on crossing FP CTO lesions, utilizing catheter-wire escalation tools alongside

various recanalization techniques and approaches. However, several limitations should be noted. Firstly, the single-center, non-randomized, retrospective design over an extended period may have been influenced by evolving techniques and tools, potentially impacting the crossing success rate. Secondly, the analysis of CTO morphology and length relied solely on intra-procedural angiography, without additional intravascular imaging, such as intravascular ultrasound or optical coherence tomography. Lastly, the timing for the distal retrograde approach was not analyzable, and no cases attempted trans-collateral approaches, potentially limiting the crossing success rate.

Conclusion

Our study highlights the safety and efficacy of utilizing the catheter-wire escalation technique alongside complex recanalization techniques and approaches for crossing FP CTO lesions. CTOP types C or D, CTO lesions at the P3-popliteal artery, the presence of severe CTO calcification (PACSS classification type 4), and underlying dyslipidemia were indicated as predictors of crossing failure. By identifying predictors of crossing failure and elucidating the role of antegrade and retrograde approaches, our findings contribute to optimizing treatment strategies and improving patient outcomes in PAD management.

Conflict of interest

The authors declare no conflicts of interest.

References

1. Beckman JA, Schneider PA, Conte MS. Advances in revascularization for peripheral artery disease: revascularization in PAD. *Circ Res* 2021;128:1885–912.
2. Regensteiner JG, Hiatt WR, Coll JR, Criqui MH, Treat-Jacobson D, McDermott MM, et al. The impact of peripheral arterial disease on health-related quality of life in the Peripheral Arterial Disease awareness, risk, and treatment: new resources for survival (PARTNERS) program. *Vasc Med* 2008;13:15–24.
3. Bernardini G, Bisdas T, Argyriou A, Saab F, Torsello G, Tsilimparis N, et al. Risk factor analysis for crossing failure in primary antegrade wire-catheter approach for femoropopliteal chronic total occlusions. *J Endovasc Ther* 2023;30:433–40.
4. Martin G, Covani M, Saab F, Mustapha J, Malina M, Patrone L. A systematic review of the ipsilateral retrograde approach to the treatment of femoropopliteal arterial lesions. *J Vasc Surg* 2021;74:1394–405.
5. Saab F, Jaff MR, Diaz-Sandoval LJ, Engen GD, McGoff TN, Adams G, et al. Chronic total occlusion crossing approach based on plaque cap morphology: the CTOP classification. *J Endovasc Ther* 2018;25:284–91.
6. Minici R, Serra R, De Rosi N, Ciranni S, Talarico M, Petullà M, et al. Endovascular treatment of femoro-popliteal occlusions with retrograde tibial access after failure of the antegrade approach. *Catheter Cardiovasc Interv* 2023;101:1108–19.
7. Shawky K, Marzouk AAE, El-Baz WA, Abd-ElHaseeb AR, Elsayed AMA, Abdelmawla MH. Superficial femoral artery chronic total occlusion crossing strategies. *Int J Health Sci* 2022;6:2438–53.
8. Wei LM, Zhu YQ, Zhang PL, Lu HT, Zhao JG. Integrated application of antegrade and retrograde recanalization for femoral-popliteal artery chronic total occlusions: outcomes compared with antegrade recanalization. *Quant Imaging Med Surg* 2018;8:568–78.
9. Itoga NK, Kim T, Sailer AM, Fleischmann D, Mell MW. Lower extremity computed tomography angiography can help predict technical success of endovascular revascularization in the superficial femoral and popliteal artery. *J Vasc Surg* 2017;66:835–43.
10. Tadano Y, Kotani J ichi, Haraguchi T, Watanabe T, Sugie T, Kaneko U, et al. Factors contributing to efficient recanalization procedures for chronic total occlusion of the superficial femoral artery. *Cardiovasc Revasc Med* 2022;37:43–9.
11. Wei LM, Zhu YQ, Zhang PL, Liu F, Lu HT, Zhao JG. Morphological characteristics of chronic total occlusion: predictors of different strategies for long-segment femoral arterial occlusions. *Eur Radiol* 2018;28:897–909.
12. Reekers JA, Bolia A. Percutaneous intentional extraluminal (subintimal) recanalization: how to do it yourself. *Eur J Radiol* 1998;28:192–8.
13. Spinosa DJ, Harthun NL, Bissonette EA, Cage D, Leung DA, Angle JF, et al. Subintimal arterial flossing with antegrade-

- retrograde intervention (SAFARI) for subintimal recanalization to treat chronic critical limb ischemia. *J Vasc Interv Radiol* 2005;16:37–44.
14. Hua WR, Yi MQ, Min TL, Feng SN, Xuan LZ, Xing J. Popliteal versus tibial retrograde access for subintimal arterial flossing with antegrade-retrograde intervention (SAFARI) technique. *Eur J Vasc Endovasc Surg* 2013;46:249–54.
 15. Igari K, Kudo T, Toyofuku T, Inoue Y. Controlled antegrade and retrograde subintimal tracking technique for endovascular treatment of the superficial femoral artery with chronic total occlusion. *Ann Vasc Surg* 2015;29:e7–10. doi:10.1016/j.avsg.2015.03.054.
 16. Grözinger G, Hallecker J, Grosse U, Syha R, Ketelsen D, Brechtel K, et al. Tibiopodal and distal femoral retrograde vascular access for challenging chronic total occlusions: predictors for technical success, and complication rates in a large single-center cohort. *Eur Radiol* 2021;31:535–42.
 17. Bhatt H, Janzer S, George JC. Crossing techniques and devices in femoropopliteal chronic total occlusion intervention. *Cardiovasc Revasc Med* 2017;18:623–31.
 18. Reis PEO, Amin A. Should re-entry devices be always available when treating chronic total occlusion? *J Vasc Endovasc Surg* 2016;1:4.
 19. Banerjee S, Sarode K, Patel A, Mohammad A, Parikh R, Armstrong EJ, et al. Comparative assessment of guidewire and microcatheter vs a crossing device-based strategy to traverse infrainguinal peripheral artery chronic total occlusions. *J Endovasc Ther* 2015;22:525–34.
 20. Hardman RL, Jazaeri O, Yi J, Smith M, Gupta R. Overview of classification systems in peripheral artery disease. *Semin Intervent Radiol* 2014;31:378–88.
 21. Rocha-Singh KJ, Zeller T, Jaff MR. Peripheral arterial calcification: prevalence, mechanism, detection, and clinical implications. *Catheter Cardiovasc Interv* 2014;83:e212–20. doi:10.1002/ccd.25387.
 22. Tummala S, Richardson AJ. Infrapopliteal artery chronic total occlusion crossing techniques: an overview for endovascular specialists. *Semin Intervent Radiol* 2021;38:492–9.
 23. Wei LM, Zhu YQ, Zhang PL, Liu F, Lu HT, Zhao JG. Correction to: morphological characteristics of chronic total occlusion: predictors of different strategies for long-segment femoral arterial occlusions. *Eur Radiol* 2018;28:2708–10.
 24. Itoga NK, Kim T, Sailer AM, Fleischmann D, Mell MW. Lower extremity computed tomography angiography can help predict technical success of endovascular revascularization in the superficial femoral and popliteal artery. *J Vasc Surg* 2017;66:835–43. doi:10.1016/j.jvs.2017.02.031.
 25. Varghese V, Virk HUH, Lakhter V, Tabaza L, Oni E, Marreddy R, et al. Femoral Artery Chronic Total Occlusion Revascularization (FACTOR) score and algorithm: feasibility and validation in a single-center study of femoropopliteal occlusions. *J Invasive Cardiol* 2020;32:e338–48.
 26. Okuno S, Iida O, Shiraki T, Fujita M, Masuda M, Okamoto S, et al. Impact of calcification on clinical outcomes after endovascular therapy for superficial femoral artery disease: assessment using the peripheral artery calcification scoring system. *J Endovasc Ther* 2016;23:731–7.
 27. Lee HY, Park UJ, Kim HT, Roh YN. The effect of severe femoropopliteal arterial calcification on the treatment outcome of femoropopliteal intervention in patients with ischemic tissue loss. *Vasc Specialist Int* 2020;36:96–104.
 28. Iida O, Takahara M, Mano T. Evidence-experience gap and future perspective on the treatment of peripheral artery disease. *J Atheroscler Thromb* 2021;28:1251–9.
 29. Aday AW, Everett BM. Dyslipidemia profiles in patients with peripheral artery disease. *Curr Cardiol Rep* 2019;21:42.
 30. Torii S, Mustapha JA, Narula J, Mori H, Saab F, Jinnouchi H, et al. Histopathologic characterization of peripheral arteries in subjects with abundant risk factors: correlating imaging with pathology. *JACC Cardiovasc Imaging* 2019;12:1501–13.
 31. Katsanos K, Tepe G, Tsetis D, Fanelli F. Standards of practice for superficial femoral and popliteal artery angioplasty and stenting. *Cardiovasc Intervent Radiol* 2014;37:592–603.
 32. Ko YG. SFA intervention: intraluminal or subintimal? *Korean Circ J* 2018;48:685–91.
 33. Ruzsa Z, Wojtasik-Bakalarz J, Nyerges A, Rakowski T, Kleczynski P, Bartus S. Long-term follow-up after retrograde recanalization of superficial femoral artery chronic total occlusion. *J Invasive Cardiol* 2017;29:336–9.