

## Optical Coherence Tomography (OCT) and OCT Angiography (OCTA) Biomarkers for Diabetic Retinopathy in Type 2 Diabetes Mellitus: A Scoping Review

Abdallah Naqaweh, B.Optom<sup>1,2</sup>, Shelina Oli Mohamed, M.D., MS<sup>3</sup>, Noor Haziq Saliman Ph.D.<sup>1</sup>

<sup>1</sup>Centre of Optometry, Faculty of Health Sciences, Universiti Teknologi MARA Puncak Alam Campus, 42300 Puncak Alam, Selangor, Malaysia.

<sup>2</sup>Faculty of Applied Medical Sciences, Department of Allied Medical Sciences, Jordan University of Science and Technology, 22110 Irbid, Jordan.

<sup>3</sup>Department of Ophthalmology, Faculty of Medicine, Hospital Al-Sultan Abdullah, Universiti Teknologi MARA Puncak Alam Campus, 42300 Puncak Alam, Selangor, Malaysia.

Received 20 September 2024 • Revised 27 September 2024 • Accepted 27 September 2024 • Published online 21 October 2024

### Abstract:

**Objective:** This scoping review aims to identify the biomarkers of optical coherence tomography (OCT) and OCT angiography (OCTA) for the assessment of diabetic retinopathy (DR) in type 2 diabetes mellitus (T2DM) patients.

**Material and Methods:** A search was conducted on multiple databases, including Scopus, ScienceDirect, WOS, and PubMed, spanning from 2015 to 2023. The criteria were selected based on the PRISMA guidelines. The search focuses on the macular OCT and OCTA biomarkers.

**Results:** The search identified 114 studies, and 20 were included in the final review. OCT findings demonstrated a reduction in the thickness of retinal layers, mainly the ganglion cell layer (GCL) and inner plexiform layer (IPL), correlating inversely with the diabetes duration. OCTA enables precise assessment of retinal vascular changes, such as the foveal avascular zone (FAZ) area and vessel density (VD), indicating DR severity. Increased FAZ area was observed in proliferative DR (PDR), and decreased VD impacted visual acuity. Other parameters (FAZ shape, circularity index, paracentral interpapillary area, fractal dimension, vessel length density, and perfusion density) are also altered in diabetic eyes. OCTA of the choriocapillaris studies reveals increased flow voids in PDR patients.

**Conclusion:** The scoping review underscores the potential application of OCT and OCTA in deciphering DR pathophysiology and highlights novel biomarkers for its detection and diagnosis. Nevertheless, longitudinal studies are warranted to

This paper was from the Memorandum of Agreement between Prince of Songkla University, Thailand and Universiti Teknologi Mara, Malaysia "Special Issue on Eye and Vision" 2024

Contact: Noor Haziq Saliman, Ph.D.

Centre of Optometry, Faculty of Health Sciences, Universiti Teknologi MARA Puncak Alam Campus, 42300 Puncak Alam, Selangor, Malaysia.

E-mail: haziqsaliman@uitm.edu.my

J Health Sci Med Res  
doi: 10.31584/jhsmr.20241102  
www.jhsmr.org

© 2024 JHSMR. Hosted by Prince of Songkla University. All rights reserved.

This is an open access article under the CC BY-NC-ND license

(<http://www.jhsmr.org/index.php/jhsmr/about/editorialPolicies#openAccessPolicy>).

validate its clinical utility. This review emphasizes the importance of advancing OCT/OCTA technology to enhance DR assessment, and ultimately improve patient care.

**Keywords:** foveal avascular zone, ganglion cell layer, OCT angiography (OCTA), optical coherence tomography (OCT), vessel density

## Introduction

Diabetic retinopathy (DR) is the most common complication of diabetes mellitus (DM) and is considered one of the main causes of blindness worldwide. The prevalence of diabetes among adults was estimated at 8.4% in 2017, and the percentage is likely to increase by 9.9% in 2045<sup>1</sup>. DR is expected to remain high, especially in Western Pacific countries; hence, visual impairment linked to DR may grow in the years ahead globally<sup>2</sup>. DR can be broadly classified into two main groups: non-proliferative diabetic retinopathy (NPDR) and proliferative diabetic retinopathy (PDR). Some studies have further classified sight-threatening DR based on the presence of neovascularization and diabetic maculopathy/diabetic macula edema<sup>3</sup>. These will impact visual functions such as blurred vision, loss of visual field, and reduced contrast sensitivity, commonly associated with DR<sup>3</sup>.

The gold standard for DR screening involves the use of non-mydriatic fundus cameras<sup>4</sup>. However, in the early stages of DR, subtle vascular changes and abnormalities are not visualized on the fundus image. They may not be a comprehensive representation of the actual DR level. Since fundus cameras only detect changes in the superficial vessels, the deep capillary inside the retina is not visible. This could affect the monitoring, follow-up and management of patients. With the seven-fields technique that gives a two-dimensional image of the retina, fundus photos can detect microaneurysms and flame-like haemorrhages. Other imaging techniques, such as fluorescein angiography, may provide a more sensitive examination of the retina; however,

the downside of the method includes being invasive, costly, time-consuming, and associated with side effects<sup>5</sup>.

Ocular coherence tomography (OCT) and OCT angiography (OCTA) are non-invasive imaging tools that provide high-resolution, well-defined images of the retinal microstructure and microvasculature. OCTA utilizes motion contrast instead of dye, enabling the detection of microvasculature in the superficial and deep capillary plexus, providing crucial insights into the intricate vascular network of the eye. These techniques have been widely used in clinical and research settings for screening or staging DR and other retinal diseases<sup>6</sup>. The common biomarkers reported in OCT studies are the retinal ganglion cell layer (GCL) and inner plexiform layer (IPL). The OCTA, on the other hand, is more diverse in assessing the microvascular alterations in different regions of the retina, including foveal avascular zone (FAZ) area, fractal dimension (FD), vessel length density (VLD) and perfusion density (PD)<sup>5</sup>. These OCTA parameters enable the visualization of the capillary plexuses at different layers, namely the superficial, intermediate and deep retinal layers<sup>5</sup>. Given this, the present review summarises the biomarkers reported in detecting DR using OCT and OCTA. The present review will also address the association between these biomarkers and DM and their appearance in different stages of DR.

## Material and Methods

The scoping review was conducted in accordance with the PRISMA-SCR guideline<sup>7</sup>, using a framework outlined by Arksey and O'Malley<sup>8</sup>, as shown in Figure 1. There are five stages involved in the scoping review: (1) identifying

the research question, (2) identifying the relevant studies, (3) study selection, (4) charting the data, and (5) collating, summarizing, and reporting the results.

### Identification of research question

The research question addressed in this review is: “What are the features of retinal microstructural and microvascular alterations observed by OCT and OCTA in patients with diabetic retinopathy?”

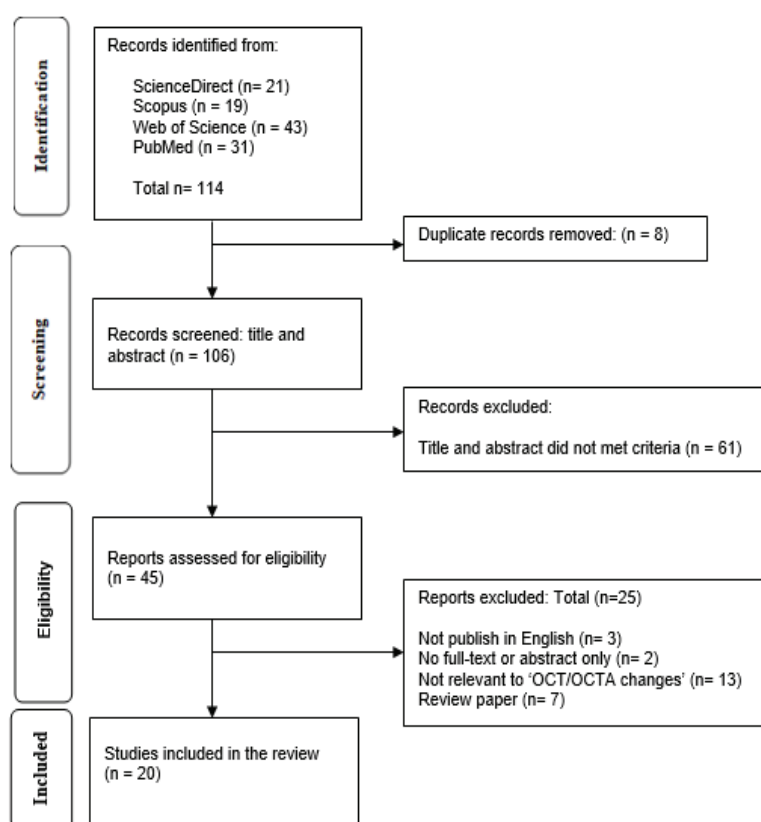
### Identification of relevant studies

Two investigators (AN and NHS) conducted the review through four electronic databases (Web of Science, Scopus, Science Direct, and PubMed). Keywords “diabetic retinopathy, biomarkers, OCT, OCTA and adults” were used, and 106 manuscripts were obtained and screened.

Duplicate records (n=8) were removed using reference management software (Mendeley).

### Selection of the studies

The inclusion criteria of the review are: (1) patients diagnosed with DR (all stages) or prediabetic retinopathy, (2) The articles were written in the English language only, (3) Adults of more than 18 years old, (4) The study participants were only diagnosed with type 2 DM (T2DM). Any records of patients with mixed diagnoses who could not obtain full-text articles, systematic reviews, audits, book reviews, opinion pieces, case studies, editorials, letters to the editor, or study protocol were excluded from this review. Following a thorough selection to satisfy the review criteria, 20 articles were selected. The flowchart of the study selection is illustrated in Figure 1.



**Figure 1** PRISMA flow chart for the study

### Charting the data

Table 1 tabulates the selected studies' data, including authors, year of publication, study design, study aims, device and software used for the image analysis, OCT and OCTA image sizes, study population, sample size, country, and summary of findings. Tables 2 and 3 tabulate the OCT and OCTA parameters investigated.

### Collating, summarizing, and reporting the results

A narrative summary of the findings is provided to condense the gathered information. The authors carried out the analysis, with the results delineated in alignment with the research questions posed in this scoping review to ensure clarity. The study specifically concentrated on the biomarkers of OCT and OCTA that could be used in detecting and staging the DR among T2DM patients.

## Results

A total of 20 articles were reviewed, including eight retrospective studies, eight prospective studies, and five cross-sectional studies. All articles investigated the application of OCT and/or OCTA in patients with DR or patients with DM without DR. The included studies were published between 2015 and 2023 and conducted in different countries, mostly in the United States of America (n=9), followed by China (n=3), Japan (n=2), and other countries, including South Korea, Egypt, India, Portugal, Switzerland and France.

Tables 2 and 3 show the overall OCT and OCTA biomarkers investigated, respectively. The most investigated OCT biomarkers were GCL and IPL; one study included the outer plexiform layer (OPL). The OCTA biomarkers were divided into two categories according to the location examined: the superficial capillary plexus (SCP) and the deep capillary plexus (DCP). The SCP includes the microvasculature from GCL to IPL, while

the DCP consists of the inner nuclear (INL) and (OPL)<sup>9</sup>. The data reported in both SCP and DCP include the FAZ parameters (area, shape, perimeter, and diameters) and blood vessel parameters (vessel density, fractal dimension, vessel length density, vessel skeletal density, perfusion density, nonperfusion area, peripapillary vessel density, and macrophage-like cells density) in the retina for each segment mentioned above. In addition, the choroidal non-flow area and flow deficit percentage were also gathered in the present review.

The most used device was the Avanti RTVue (Optovue, Fremont, California) for OCT and OCTA imaging (9 out of 20 studies), followed by Zeiss Cirrus (Carl Zeiss Meditec, Dublin, CA, USA) (3 out of 20 studies). Different types of image analysis were reported across the 20 studies; however, the open-source software ImageJ (National Institutes of Health, Bethesda, MD, USA) recorded the highest utilization for image analysis (10 out of 20 studies).

### OCT biomarkers

A few studies reported the thinning of GCL and IPL in patients with NPDR and DM without DR compared to healthy subjects. These two neural layers positively correlated with VD in SCP and DCP<sup>10,11</sup>. Al-Nashar et al.<sup>12</sup> discovered that a reduction in GCL and IPL thicknesses was significantly associated with an increase in FAZ area. A similar correlation trend was also reported between OPL and FAZ area<sup>13</sup>.

### OCTA biomarkers

FAZ area is defined as the foveal area that is void of blood vessels measured per millimetre square. Enlargement of this area in SCP and DCP was evident in patients with DM compared to healthy individuals<sup>12,14-18</sup>. Samara et al.<sup>18</sup> and Garg et al.<sup>19</sup> reported an increase in FAZ area in PDR compared to controls, negatively correlated with best-corrected visual acuity. Gozlan et al.<sup>9</sup>, on the

**Table 1** Summary of the articles included in the review

Author(s)/ Year	Study design	Aim	Device/image analysis software	OCT/OCTA field size	Study population	Summary of Findings
Takase et al. <sup>14</sup> (2015)	Retrospective Chart Review	To evaluate the FAZ area in healthy and diabetic eyes	Avanti RTVue XR / ImageJ	OCTA: 3 mm x 3 mm	DR (n=20) NDR (n=24) Control (n=19)	The FAZ area in diabetic eyes is larger than in healthy eyes (p-value<0.01)
Salz et al. <sup>15</sup> (2016)	Cross-sectional	To evaluate the potential clinical utility of OCTA and compare it with FA	Prototype ultra-high-speed SS-OCT / Axis Image Management	OCTA: 3 mm x 3 mm 6 mm x 6 mm	T2DM (n=43) Control (n=11)	The FAZ area increased in diabetic eyes compared to control.
Li et al. <sup>13</sup> (2017)	Cross-sectional	To compare inter-retinal thickness between DM and control	Spectralis SD-OCT / -	OCT: 9.1 mm x 7.6 mm	NDR (n=133) DR (n=42) Control (n=115)	IRL thicknesses was decreased in NDR compared with controls, OPL was thinner in NDR vs DR
Bhardwaj et al. <sup>24</sup> (2018)	Retrospective	To use FD analysis to investigate retinal vascular disease patterns in DR patients.	Avanti RTVue XR / ImageJ	OCTA: 3 mm x 3 mm	DR (n=58) Control (n=49)	DR patients had less FD compared to the control in both SCP and DCP
Hirano et al. <sup>23</sup> (2018)	Prospective Cross-sectional	To evaluate quantitative metrics of retinal microvasculature in eyes with DR	PLEX Elite 9000, Carl Zeiss / ImageJ	OCTA: 3 mm x 3 mm 6 mm x 6 mm	NDR (n=10) DR (n=36) Control (n=16)	PD, VLD and FD decreased with the severity of DR in SCP, DCP, and full thickness slab
Shin et al. <sup>11</sup> (2019)	Cross-sectional	To evaluate the changes in peripapillary microvascular parameters in DM eyes	Zeiss Cirrus HD-OCT 5000 with Angio Plex / AngioPlex software	OCT: 12 mm x 12 mm macular cube 512 x 128 protocol OCTA: 6 mm x 6 mm	NDR (n=40) DR (n=31) Control (n=50)	Lower VD and PD in NDR and DR compared to control. Thinner mGC-IPL and pRNFL in NDR and DR compared to control.
Marques et al. <sup>10</sup> (2021)	Longitudinal prospective	To examine the retinal changes in the initial stages of NPDR and progression	Zeiss Cirrus HD-OCT 5000 with Angio Plex / Carl Zeiss Meditec Density Exerciser	OCT: The Macular Cube 512 x 128 protocol OCTA: 3 mm x 3 mm	DR (n=78) Control (n=84)	A higher decrease in VD and PD is shown in eyes with worse stages of retinopathy.
Chen et al. <sup>30</sup> (2023)	Longitudinal prospective	To investigate the relationship between OC FD% and DR progression and DME development	Triton SS-OCT / Fiji, ImageJ software	OCTA: 3 mm x 3 mm	NDR (n=1805)	OC FD% was higher in patients with DR progression and in inferior and nasal sectors of patients with DME development
Wang et al. <sup>22</sup> (2023)	Retrospective cross-sectional	To quantitatively analyze the MLCs at VRI	SVision Imaging VG100 / ImageJ	OCTA: 6 mm x 6 mm	DR (n=190) Control (n=63)	VD in DCP vs MLC density MLC density is higher in PDR and DME VD in DCP, CFT, and MRT decreased in DR vs control.
Garg et al. <sup>19</sup> (2022)	Cross-sectional	To study OCTA metrics in diagnosing and staging DR	PLEX Elite 9000, Carl Zeiss / Fiji, ImageJ software	OCTA: 6 mm x 6 mm 12 mm x 12 mm	NDR (n=51) DR (n=353) Control (n=69)	MLC density increased in DR vs control VD and SD in SCP decreased in DR progression while increasing NPA. Decrease in VD and SD in DCP in early DR

Table 1 (continued)

Author(s)/ Year	Author(s)/ Year	Aim	Device/image analysis software	OCT/OCTA field size	Study population	Summary of Findings
Al-Nashar & Al-Bialy <sup>12</sup> (2022)	Prospective study	To evaluate the correlation between foveal microvasculature and IRL thinning in T2DM	RTVue-XR Avanti / Angiovue software	OCT: 5 mm macular scan OCTA: 6 mm x 6 mm	Diabetic (n=50) Control (n=50)	FAZ area is larger in the Diabetic group vs the control. Decrease in parafoveal and perifoveal VD in DCP and SCP in the diabetic group vs control. IRL correlated with VD and FAZ area in Diabetic group
Ong et al. <sup>28</sup> (2021)	Prospective Cross-sectional	To quantitatively characterize MLCs in different severity of DR	RTVue-XR Avanti / Fiji, ImageJ software	OCTA: 3 mm x 3 mm	NDR (n=22) DR (n=32)	MLC density was found higher in PDR compared with other groups
Agemy et al. <sup>26</sup> (2015)	Retrospective review	To map retinal vascular perfusion using OCTA in DR and control subjects	RTVue-XR Avanti / Angiovue software	OCTA: 3 mm x 3 mm 6 mm x 6 mm	Control (n=18) DR (n=56) Control (n=21)	Reduce PD in all segments studied in DR vs controls.
Freiberg et al. <sup>20</sup> (2015)	Retrospective	To analyze FAZ dimensions and symmetry in DR compared with control	RTVue-100 XR Avanti / ImageJ	OCT: 20°x15° OCTA: 2 mm x 2 mm	DR (n=29) Control (n=25)	FAZ diameters (horizontal, Vertical and maximum) were larger in the DR group compared to control.
Bhanushali et al. <sup>16</sup> (2016)	Prospective Cross-sectional	To correlate retinal vascular parameters with the severity of DR	AngioVue Optovue / Angiovue software	OCTA: 3 mm x 3 mm	DR (n=209) Control (n=60)	Lower FAZ area in Control Higher VD in control Lower spacing between large and small vessels compared to DR.
Kim et al. <sup>21</sup> (2016)	Retrospective Cross-sectional	To quantify the retinal microvasculature in DR	Zeiss Cirrus prototype / MATLAB	OCTA: 3 mm x 3 mm	DR (n=84) Control (n=14)	Decreasing in SD, VD and FD with increasing in VDI were signs of progression in DR.
Al-Sheikh et al. <sup>17</sup> (2016)	Prospective	To compare FAZ area and macular network density in DR and normal individuals	DRI OCT Triton Topcon / GIMP software	OCTA: 3 mm x 3 mm	DR (n=28) Control (n=40)	Lower VD and bigger FAZ area in both SCP and DCP found in DR patients compared with control.
Samara et al. <sup>18</sup> (2017)	Retrospective	To quantify FAZ area and macular vascular density	RTVue-XR Avanti / Angiovue software	OCTA: 3 mm x 3 mm	DR (n=84) Control (34)	FAZ area was greater in both Superficial and deep networks. Lower VAD and VLD in both superficial and deep networks in patients with DR compared with normal.
Gozian et al. <sup>9</sup> (2017)	Cross-sectional	To investigate the FAZ and perifoveal microcirculation changes	RTVue-XR Avanti, DRI OCT-1 Atlantis Topcon / ImageJ	OCTA: 3 mm x 3 mm	DR (n=58)	Progression between DR and FAZ grade, surface, perimeter and NPI in SCP
Dodo et al. <sup>29</sup> (2017)	Retrospective	To provide insights into the role of disrupted chorioidal circulation in DR	RTVue XR Avanti Optovue / ImageJ	OCTA: 3 mm x 3 mm	NDR (n=11) DR (n=97)	Non-flow areas in CSF increased with RR progression

CC-FD=choriocapillaris flow deficit, CSF=central subfield, DME=diabetic macular edema, DR=diabetic retinopathy, DCP=deep capillary plexus, FD=fractal dimension, FAZ=foveal avascular zone, IRL=inner retinal layer, MLC=macrophage-like cell, mGC-IPL=macular ganglion cell-inner plexiform layer, NDR=diabetic with no retinopathy, NPDR=non-proliferative diabetic retinopathy, NPA=nonperfusion area, NPI=nonperfusion index, OPL=outer plexiform layer, PD=perfusion density, pRNFL=peripapillary retinal nerve fiber layer, PDR=proliferative diabetic retinopathy, SD=skeletonized density, SCP=superficial capillary plexus, T2DM=type 2 diabetes mellitus, VAD=vessel area density, VD=vessel density, VDI=vessel diameter index, VLD=vessel length density, VRI=vitreoretinal interface

**Table 2** OCT biomarkers taken from the microstructural layers of the retina

Types of microstructure alteration				
Region	Category	Measurements	Layers	Reviewed articles
Macula	Neural layers	Thickness--	Ganglion cell layer (GCL)	Marques et al. <sup>10</sup> (2021), Shin et al. <sup>11</sup> (2019), Al-Nashar&Al-Bialy <sup>12</sup> (2022), Li et al. <sup>13</sup> (2017)
			Inner plexiform layer (IPL)	Marques et al. <sup>10</sup> (2021), Shin et al. <sup>11</sup> (2019), Al-Nashar&Al-Bialy <sup>12</sup> (2022), Li et al. <sup>13</sup> (2017)
			Outer plexiform layer (OPL)	Li et al. <sup>13</sup> (2017)

**Table 3** OCTA biomarkers taken from the ocular microvasculature

Types of microvascular alterations				
Zone	Region	Sub-category	Parameters	Reviewed articles
Superficial capillary plexus (SCP)	Macular GCL-IPL	Foveal avascular zone (FAZ)	FAZ area	Gozlan et al. <sup>9</sup> (2017), Al-Nashar&Al-Bialy <sup>12</sup> (2022), Takase et al. <sup>14</sup> (2015), Salz et al. <sup>15</sup> (2016), Bhanushali et al. <sup>16</sup> (2016), Garg et al. <sup>19</sup> (2022)
			FAZ shape	Gozlan et al. <sup>9</sup> (2017), Marques et al. <sup>10</sup> (2021), Garg et al. <sup>19</sup> (2022), Freiberg et al. <sup>20</sup> (2016)
			FAZ perimeter	Gozlan et al. <sup>9</sup> (2017)
			FAZ diameter	Freiberg et al. <sup>20</sup> (2016)
		Blood Vessels	Vessel density (VD) and	Marques et al. <sup>10</sup> (2021), Al-Sheikh et al. <sup>17</sup> (2016), Samara et al. <sup>18</sup> (2017), Garg et al. <sup>19</sup> (2022), Kim et al. <sup>21</sup> (2016), Wang et al. <sup>22</sup> (2023)
			Vessel length density	Garg et al. <sup>19</sup> (2022), Kim et al. <sup>21</sup> (2016), Hirano et al. <sup>23</sup> (2019)
			Fractal dimension (FD)	Kim et al. <sup>21</sup> (2016), Hirano et al. <sup>23</sup> (2019), Bhardwaj et al. <sup>24</sup> (2018)
			Perfusion density (PD)	Marques et al. <sup>10</sup> (2021), Hirano et al. <sup>23</sup> (2019), Agemy et al. <sup>26</sup> (2015)
			Nonperfusion area (NPA)	Gozlan et al. <sup>9</sup> (2017), Garg et al. <sup>19</sup> (2022)
Deep capillary Plexus (DCP)	Macular INL-OPL	Foveal avascular zone (FAZ)	FAZ Area	Gozlan et al. <sup>9</sup> (2017), Al-Nashar&Al-Bialy <sup>12</sup> (2022), Takase et al. <sup>14</sup> (2015), Salz et al. <sup>15</sup> (2016), Bhanushali et al. <sup>16</sup> (2016), Al-Sheikh et al. <sup>17</sup> (2016), Samara et al. <sup>18</sup> (2017), Garg et al. <sup>19</sup> (2022), Gozlan et al. <sup>9</sup> (2017), Freiberg et al. <sup>20</sup> (2016)
			FAZ shape	Gozlan et al. <sup>9</sup> (2017)
			FAZ perimeter	Gozlan et al. <sup>9</sup> (2017)
			FAZ diameter	Freiberg et al. <sup>20</sup> (2016)
		Blood vessels	Vessel density (VD) and	Marques et al. <sup>10</sup> (2021), Samara et al. <sup>18</sup> (2017), Garg et al. <sup>19</sup> (2022), Kim et al. <sup>21</sup> (2016), Wang et al. <sup>22</sup> (2023)
			Vessel length density	Garg et al. <sup>19</sup> (2022), Hirano et al. <sup>23</sup> (2019)
			Fractal dimension (FD)	Kim et al. <sup>21</sup> (2016), Hirano et al. <sup>23</sup> (2019), Bhardwaj et al. <sup>24</sup> (2018)
Macrophage-like cell layer	5 to 10 µm above the ILM	Macrophage-like cells (MLCs)	MLCs density	Wang et al. <sup>22</sup> (2023), Ong et al. <sup>28</sup> (2021)
Choroid and choriocapillaris	from 31 to 40 µm posterior to the RPE-Bruch membrane complex	Blood vessels	Flow void	Dodo et al. <sup>29</sup> (2017) Chen et al. <sup>30</sup> (2023),



other hand, reported an enlargement of the FAZ area with the progression of NPDR, which positively correlated with glycated haemoglobin (HbA1c) readings.

**FAZ shape:** This parameter is a quantitative measure of the circularity index, mainly the FAZ uniformity, which can have values from 0 to 1, in which 1 is a perfect circle, and 0 is an irregular shape<sup>9</sup>. FAZ shape in SCP was found to be decreased in diabetic eyes, and this worsened with the progression of DR as compared to healthy individuals<sup>10,19</sup>. Alternatively, FAZ shape was also reported using qualitative grading of the ETDRS grading system from 0 to 4, where an increase in grade indicates the enlargement of the FAZ area<sup>9</sup>. Gozlan et al. showed that increasing severity of DR was associated with higher FAZ grade, higher HbA1c, and reduced best-corrected visual acuity<sup>9,19</sup>. Freiberg et al.<sup>20</sup> reported that the circularity index of FAZ in DR eyes is asymmetrical with gaps and holes. At the same time, healthy individuals acquired more like an oval-shaped FAZ without gaps or holes in SCP and DCP.

**FAZ perimeter and diameter:** These parameters were recorded in SCP and DCP. An increase in the FAZ perimeter was correlated with increased severity of DR and positively correlated with HbA1c<sup>9</sup>. Meanwhile, the FAZ diameter (the maximum measurement in mm within the FAZ area) was reported to be larger in DR patients compared to healthy controls and correlated with reduced visual acuity<sup>20</sup>.

**Vessel density (VD):** VD is defined as the overall area of blood vessels adequately supplied with blood per unit area within a specific measurement of region<sup>19</sup>. A few reports found that a decrease in VD in the whole retina layers correlates with the severity of DR compared to control<sup>18,19,21</sup>. A significant reduction in VD was also found in DCP<sup>22</sup> and SCP<sup>10,17</sup> layers. Furthermore, there were reports of a substantial decrease in VD of DCP and SCP with DR progression<sup>10,18,19,21,22</sup>.

**Vessel length density (VLD):** VLD is defined as vessel length per unit area based on a skeletonized image;

VLD can be evaluated by dividing the summation of the pixels occupied by the vessel length in the skeletonized image by all the pixels in the image squared<sup>21</sup>. VLD was greater in healthy eyes than in DR eyes in both SCP and DCP and decreased by the severity of DR<sup>19,23</sup>. The same results were found in SCP only with Hirano et al.<sup>23</sup>

**Fractal dimension (FD):** FD is defined as the complexity of vascular branching on binarized images<sup>21</sup>. FD was found to be decreased in DR patients compared to healthy individuals in SCP, DCP, and full retinal plexus<sup>21,23,24</sup>. A decrease in FD between DR groups was found in SCP and full retina between mild NPDR, severe NPDR and PDR<sup>21,23,34</sup>. However, a significant difference between NPDR stages was found only in DCP<sup>21,24</sup>.

**Perfusion Density (PD):** PD is the proportion of space occupied by blood vessels compared to the entire area of the image<sup>25</sup>. A significant reduction of PD in SCP was reported among mild DR patients compared to healthy individuals<sup>10,23,26</sup>.

**Nonperfusion area (NPA):** NPA refers to insufficient perfusion of the retinal blood flow, which is considered a sign of ischemia<sup>27</sup>. The NPA increases as the severity of DR progresses<sup>19</sup>. Another report investigated the nonperfusion index (NPI), which can be calculated by taking the ratio between the cumulative area of pixels with low brightness to the total area of the picture, and again, a similar trend was reported<sup>9</sup>. These findings, however, were only reported in SCP. Besides that, a positive correlation was recorded between NPI and the duration of DM, HbA1c levels, and reduction in visual performance<sup>9</sup>.

**Macrophage-like cell density (MLC):** MLC is defined as the number of cells (presumably inflammatory cells) per unit area. Only two studies have investigated this parameter, and both found higher MLC counts in PDR compared to NPDR<sup>22,28</sup>. ONG et al. found MLC in PDR around 3.5 times higher than in healthy people.



Flow Void (FV): FV is the proportion of the area where flow falls below a set threshold relative to the total area of the scanned region and appears like dark regions in the image<sup>29</sup>. The flow void in the choriocapillaris segment was higher in severe NPDR and PDR than in healthy eyes<sup>29</sup> and increased gradually with the severity of DR<sup>30</sup>.

Peripapillary OCTA: Shin et al.<sup>11</sup> observed changes in peripapillary microvasculature, with the overall peripapillary area larger in healthy eyes compared to DM eyes. In addition, the peripapillary microvasculature in the inferior segments was reported to be significantly decreased in DM eyes compared to healthy eyes.

## Discussion

This scoping review discussed the potential application of OCT and OCTA at different stages of DR. The information acquired from the 20 studies in this review may be a springboard for a more robust study design to support the current literature.

OCT provides three-dimensional images showing the thickness of retinal layers, including both neural and non-neural layers. Information about the microstructure of the retinal layers helps us understand the pathophysiology of DR<sup>30</sup>. Measurements such as retinal layer thickness, FAZ area, and VD can be useful for determining the severity of DR by staging and monitoring the disease progression. For instance, in an animal study, reduction in the retinal nerve fibre layer and GCL was used to determine the type of treatment, such as nerve growth factor treatment<sup>31</sup>.

In general, novel biomarkers are important because they could be linked to how a disease progresses and reacts to treatments<sup>30</sup>. OCT has been proposed as an additional biomarker for assessing the severity of DR, particularly in detecting edema and fundus cameras<sup>30</sup>. However, it has not yet been conclusive for other types of retinal complications in DR. The present review found a significant reduction in the thickness of the subfoveal retina and the neural

retinal layers (GCL and IPL) in patients with DR<sup>10-13</sup>. This trend was noted across all types of DR severity<sup>32</sup>. Pires et al. showed a thickening in the retinal layers, which was suggested to occur due to fluid buildup in the retina<sup>33</sup>. The contradictions may be explained by the type of DR patients investigated, where Pires et al.<sup>33</sup> examined mild NPDR patients, suggesting the fluid influx might occur at the early stage of DR.

GCL and IPL may enhance the understanding of microstructural changes and their association with other risk factors. Furthermore, they could be the focus of therapeutic targets aimed at preventing the progression of neurodegenerative changes related to DR. The theory of retinal neurodegeneration in diabetic patients is supported by the gradual diminution of retinal thicknesses, primarily in the GCL and IPL, resulting from inner retinal tissue loss<sup>34</sup>. This neurodegeneration process is believed to develop before the commencement of diabetic microvascular alterations, which are observable using OCT<sup>34</sup>.

Regarding OCTA, the present review defines SCP as the region extending from 3µm below the inner limiting membrane to 15µm below the IPL. The deep capillary plexus (DCP) is the region in the retina that starts from the end of SCP to 70µm below IPL, including the INL and OPL. Hence, both terms are adopted in the present review to represent the respective retinal macular regions.

DR can be visualized and, more precisely, identified through the alterations of the microvascular perfusion. These alterations are observable at different retina layers, more commonly at the SCP and DCP<sup>6</sup>. The present review found that FAZ and VD are the most widely investigated parameters in DR using OCTA. Other biomarkers investigated include FD, PD, NPA, and MLC. Seven out of eight articles investigated the FAZ. They found an increase in the area at SCP and DCP in diabetic eyes compared to healthy individuals, noting the largest FAZ area recorded in PDR patients<sup>12,14-19</sup>. Between DR stages,

the FAZ area shows an increment trend as the DR severity progresses<sup>9,18,19</sup>. One potential reason could be the capillary closure or abnormalities in capillary endothelium attributed to the hyperglycemia<sup>35</sup>. Further understanding is still being sought for the mechanisms related to these changes in OCTA and its associations with systemic risk factors and progression. It is proposed that FAZ enlargement could serve as a biomarker linked to macula ischaemia, which has a predictive value in the visual outcomes of patients.

Besides FAZ area, FAZ shape is a common biomarker investigated in DR studies by measuring the horizontal and vertical FAZ diameters<sup>10,19,20</sup>. One study reported that DR patients exhibit an irregular FAZ shape compared to a regular shape observed in healthy controls<sup>20</sup>. This relates to the circularity index, which has been shown to be reduced with the progression of DR<sup>10,19</sup>, indicating a good biomarker for the detection and staging of DR<sup>36</sup>.

VD has also been a matter of discussion for DR in OCTA studies. Four out of seven articles found a significant reduction in VD in T2DM patients in the whole retina layers<sup>17–19,21</sup> and worsened as the DR severity progresses<sup>36</sup>. One potential reason could be that hyperglycemia induces reduced retinal blood flow, increasing inflammatory cell adherence to retinal blood vessels and causing capillary obstruction. The impact of these complications may then lead to a decrease in VD<sup>35</sup>. Despite that, one study found the reduction was only evident in the DCP, suggesting this layer may play a major role in assessing DR severity<sup>18</sup>. Other studies reported similar outcomes on vessel length density (VLD). They suggested it should also be considered one of the biomarkers in evaluating DR severity<sup>19,21,23</sup>. A study reported that peripapillary VD and VLD were significantly reduced in the later stage of DR<sup>11</sup>. These changes may be attributed to the alteration of the papillary retinal nerve fibre layer, suggesting the neurodegeneration around the optic nerve area occurs before the microvascular changes<sup>11</sup>.

Three studies reported a reduction of FD in DR patients compared to healthy controls<sup>21,23,24</sup>. However, the study's sample size could have been more homogenous between the two groups. Hence, robust research is warranted to confirm the findings. Future studies using a larger sample size for DR and control groups with longitudinal follow-up before the development of DR and following the presence of various stages of DR may enhance the understanding of these OCTA biomarkers and their relationship with the progression of DR.

On the other hand, PD was found to be reduced in T2DM, particularly at the SCP<sup>10,23,26</sup>, contrary to prediabetic patients, which showed an increased trend compared to control<sup>37</sup>. The explanation behind this discrepancy needs to be better understood. However, the impact of hyperglycemia on retinal perfusion is more apparent in T2DM patients than in prediabetic patients.

Nonperfusion area (NPA) is another OCTA biomarker that is shown to be directly proportional to DR severity<sup>19</sup>. One study using the respective ultra-wide field OCTA (12mm x 12mm) and ultra-widefield fundus angiography found that the earliest changes in NPA were detected at the mid-peripheral and peripheral regions of the retina<sup>38</sup>. This mimics the typical sign of an ischemic retina, which commonly presents like a cotton wool spot sign from retinal vascular endothelial dysfunction due to hyperglycemia.

MLCs were reported to increase as DR progresses<sup>22,28</sup>. The trend was reported in the later stage of DR, including PDR and diabetic macular edema. Another sign is the uneven distribution of MLCs among DR patients. Wang et al.<sup>22</sup> found a negative correlation between MLCs and VD in DCP, which was proposed to be directly related to the DR progression. This trend was also supported by a previous animal study<sup>39</sup>. One potential reason could be DR induces endothelial injury and pericyte depletion, impairing the blood-retinal barrier, consequently causing these MLCs to originate from

monocyte-derived macrophages within the compromised vasculature<sup>39</sup>.

Evaluation of choroidal blood flow is crucial for understanding the development of diabetic eye diseases. However, measuring its blood flow is challenging. OCTA allows the visualization of the blood flow in choriocapillaris (CC) using flow voids (FV) to analyze CC perfusion. This technique is better at detecting abnormalities in the choroidal vessels than measuring the vascular density due to its dense and small interpapillary distance of the OCTA resolution<sup>40</sup>. FV at the choriocapillaris segment was reported to be positively correlated with DR severity<sup>37,38</sup>. This observation explains that flow defects in the choroidal capillaries may serve as an additional biomarker in response to systemic inflammatory diseases like DM<sup>38</sup>.

### Limitations

The current scoping review excludes articles written in languages other than English. Therefore, some findings could not be included, although the number of such articles is minimal. Furthermore, the present review did not include diabetic macular edema as being of interest due to its complexity and multifactorial nature.

### Conclusion

This review presents insights into retinal biomarkers for assessing DR using OCT and OCTA. Most articles discussed in this review primarily used a cross-sectional approach comparing the DR groups and controls, providing promising indicators of DR biomarkers. This approach takes little time, like prospective studies, and does not rely on previous data that may exist or not, like retrospective studies. OCT reveals reductions in the thickness of retinal layers correlating with disease duration, while OCTA enhances visualization of vascular alterations. Key parameters such as FAZ area and VD may be the main biomarkers for assessing and monitoring DR severity. Other parameters, including

FAZ shape, circularity index, and morphologic vascular features, may offer additional insights. Despite the limitations of heterogeneous methodologies and small sample sizes, these findings underscore the importance of future research and improved clinical protocols. Future studies may investigate the microstructural and microvascular alterations in DM patients with no clinically apparent DR. It is important for these two assessments to be carried out early as DR is irreversible. Ultimately, the advancement in OCT and OCTA technology is beneficial and worthy in aiding DR diagnosis and enhancing patient care.

### Funding sources

This research is funded by the Ministry of Higher Education under Fundamental Research Grants Scheme 2024 (FRGS/1/2024/SKK06/UITM/02/2).

### Conflict of interest

There are no potential conflicts of interest to declare.

### References

1. Cho NH, Shaw JE, Karuranga S, Huang Y, Da Rocha Fernandes JD, Ohlrogge AW, et al. IDF Diabetes Atlas: Global estimates of diabetes prevalence for 2017 and projections for 2045. *Diabetes Res Clin Pract* 2018;138:271–81. doi: 10.1016/j.diabres.2018.02.023.
2. Teo ZL, Tham YC, Yu M, Chee ML, Rim TH, Cheung N, et al. Global prevalence of diabetic retinopathy and projection of burden through 2045. *Ophthalmology* 2021;128:1580–91. doi: 10.1016/j.ophtha.2021.04.027.
3. Yang Z, Tan TE, Shao Y, Wong TY, Li X. Classification of diabetic retinopathy: Past, present and future. *Front Endocrinol (Lausanne)* 2022;13. doi: 10.3389/fendo.2022.1079217.
4. The Vision Academy, Lanzetta P, Sarao V, Scanlon PH, Barratt J, Porta M, et al. Fundamental principles of an effective diabetic retinopathy screening program. *Acta Diabetol* 2020;57:785–98. doi: 10.1007/s00592-020-01506-8.
5. Pramili V, Levine ES, Waheed NK. Macular vessel density in diabetic retinopathy patients: how can we accurately measure

- and what can it tell us? *Clin Ophthalmol* 2021;15:1517–27. doi: 10.2147/OPTH.S272328.
6. Rocholz R, Corvi F, Weichsel J, Schmidt S, Staurengi G. Oct angiography (OCTA) in retinal diagnostics. In: *High resolution imaging in microscopy and ophthalmology*. Springer Cham 2019:135–160. doi: 10.1007/978-3-030-16638-0\_6.
  7. Tricco AC, Lillie E, Zarin W, O'Brien KK, Colquhoun H, Levac D, et al. PRISMA extension for scoping reviews (PRISMA-ScR): checklist and explanation. *Ann Intern Med* 2018;169:467–73. doi: 10.7326/M18-0850.
  8. Arksey H, O'Malley L. Scoping studies: towards a methodological framework. *Int J Soc Res Methodol* 2005;8:19–32. doi: 10.1080/1364557032000119616.
  9. Gozlan J, Ingrand P, Lichtwitz O, Cazet-Supervielle A, Benoudis L, Boissonnot M, et al. Retinal microvascular alterations related to diabetes assessed by optical coherence tomography angiography. *Medicine (United States)* 2017;96. doi: 10.1097/MD.00000000000006427.
  10. Marques IP, Kubach S, Santos T, Mendes L, Madeira MH, De Sisternes L, et al. Optical coherence tomography angiography metrics monitor severity progression of diabetic retinopathy—3-year longitudinal study. *J Clin Med* 2021;10. doi: 10.3390/jcm10112296.
  11. Shin YI, Nam KY, Lee SE, Lee MW, Lim HB, Jo YJ, et al. Peripapillary microvasculature in patients with diabetes mellitus: An optical coherence tomography angiography study. *Sci Rep* 2019;9. doi: 10.1038/s41598-019-52354-8.
  12. Al-Nashar H, Al-Bialy H. Correlation between foveal microvasculature and inner retinal layer thickness in type 2 diabetes: an optical coherence tomography angiography study. *Delta J Ophthalmol* 2022;23:50. doi: 10.4103/djo.djo\_13\_21.
  13. Li ST, Wang XN, Du XH, Wu Q. Comparison of spectral-domain optical coherence tomography for intra-retinal layers thickness measurements between healthy and diabetic eyes among Chinese adults. *PLoS One* 2017;12. doi: 10.1371/journal.pone.0177515.
  14. Takase N, Nozaki M, Kato A, Ozeki H, Yoshida M, Ogura Y. Enlargement of foveal avascular zone in diabetic eyes evaluated by en face optical coherence tomography angiography. *Retina* 2015;35:2377–83. doi: 10.1097/IAE.0000000000000849.
  15. Salz DA, de Carlo TE, Adhi M, Moul E, Choi W, Bauman CR, et al. Select features of diabetic retinopathy on swept-source optical coherence tomographic angiography compared with fluorescein angiography and normal eyes. *JAMA Ophthalmol* 2016;134:644–50. doi: 10.1001/jamaophthalmol.2016.0600.
  16. Bhanushali D, Anegondi N, Gadde SG, Srinivasan P, Chidambara L, Yadav NK, et al. Linking retinal microvasculature features with severity of diabetic retinopathy using optical coherence tomography angiography. *Invest Ophthalmol Vis Sci* 2016;57:519–25. doi: 10.1167/iov.15-18901.
  17. Al-Sheikh M, Akil H, Pfau M, Sadda SR. Swept-source OCT angiography imaging of the foveal avascular zone and macular capillary network density in diabetic retinopathy. *Invest Ophthalmol Vis Sci* 2016;57:3907. doi:10.1167/iov.16-19570.
  18. Samara WA, Shahlaee A, Adam MK, Khan MA, Chiang A, Maguire JL, et al. Quantification of diabetic macular ischemia using optical coherence tomography angiography and its relationship with visual acuity. *Ophthalmology* 2017;124:235–44. doi: 10.1016/j.ophtha.2016.10.008.
  19. Garg I, Uwakwe C, Le R, Lu ES, Cui Y, Wai KM, et al. Nonperfusion area and other vascular metrics by wider field swept-source OCT angiography as biomarkers of diabetic retinopathy severity. *Ophthalmol Sci* 2022;2:100144. doi: 10.1016/j.xops.2022.100144.
  20. Freiberg FJ, Pfau M, Wons J, Wirth MA, Becker MD, Michels S. Optical coherence tomography angiography of the foveal avascular zone in diabetic retinopathy. *Graefes Arch Clin Exp Ophthalmol* 2016;254:1051–8. doi: 10.1007/s00417-015-3148-2.
  21. Kim AY, Chu Z, Shahidzadeh A, Wang RK, Puliafito CA, Kashani AH. Quantifying microvascular density and morphology in diabetic retinopathy using spectral-domain optical coherence tomography angiography. *Invest Ophthalmol Vis Sci* 2016;57:OCT362–OCT370. doi: 10.1167/iov.15-18904.
  22. Wang W, Sun G, Xu A, Chen C. Proliferative diabetic retinopathy and diabetic macular edema are two factors that increase macrophage-like cell density characterized by en face optical coherence tomography. *BMC Ophthalmol* 2023;23. doi: 10.1186/s12886-023-02794-8.
  23. Hirano T, Kitahara J, Toriyama Y, Kasamatsu H, Murata T, Sadda S. Quantifying vascular density and morphology using different swept-source optical coherence tomography angiographic scan patterns in diabetic retinopathy. *Br J Ophthalmol* 2019;103:216–21. doi:10.1136/bjophthalmol-2018-311942.

24. Bhardwaj S, Tsui E, Zahid S, Young E, Mehta N, Agemy S, et al. Value of fractal analysis of optical coherence tomography angiography in various stages of diabetic retinopathy. *Retina* 2018;38:1816–23. doi: 10.1097/IAE.0000000000001774.
25. Yospon T, Rojananuangnit K. Optical coherence tomography angiography (OCTA) differences in vessel perfusion density and flux index of the optic nerve and peri-papillary area in healthy, glaucoma suspect and glaucomatous eyes. *Clin Ophthalmol* 2023;17:3011–21. doi: 10.2147/OPTH.S429718.
26. Agemy SA, Sripsema NK, Shah CM, Chui T, Garcia PM, Lee JG, et al. Retinal vascular perfusion density mapping using optical coherence tomography angiography in normals and diabetic retinopathy patients. *Retina* 2015;35:2353–63. doi: 10.1097/IAE.0000000000000862.
27. Hwang TS, Gao SS, Liu L, Lauer AK, Bailey ST, Flaxel CJ, et al. Automated quantification of capillary nonperfusion using optical coherence tomography angiography in diabetic retinopathy. *JAMA Ophthalmol* 2016;134:367. doi: 10.1001/jamaophthalmol.2015.5658.
28. Ong JX, Nesper PL, Fawzi AA, Wang JM, Lavine JA. Macrophage-like cell density is increased in proliferative diabetic retinopathy characterized by optical coherence tomography angiography. *Invest Ophthalmol Vis Sci* 2021;32. doi: 10.1167/iovs.62.10.2.
29. Dodo Y, Suzuma K, Ishihara K, Yoshitake S, Fujimoto M, Yoshitake T, et al. Clinical relevance of reduced decorrelation signals in the diabetic inner choroid on optical coherence tomography angiography. *Sci Rep* 2017;7. doi: 10.1038/s41598-017-05663-9.
30. Chen Y, Zhu Z, Cheng W, Bulloch G, Chen Y, Liao H, et al. Choriocapillaris flow deficit as a biomarker for diabetic retinopathy and diabetic macular edema: 3-year longitudinal cohort. *Am J Ophthalmol* 2023;248:76–86. doi: 10.1016/j.ajo.2022.11.018.
31. Zerbini G, Maestroni S, Viganò I, Mosca A, Paleari R, Gabellini D, et al. Progressive thinning of retinal nerve fiber layer/ganglion cell layer (RNFL/GCL) as biomarker and pharmacological target of diabetic retinopathy. *Int J Mol Sci* 2023;24:12672. doi: 10.3390/ijms241612672.
32. Ulhaq ZS, Hasan YTN, Herawangsa S, et al. The retinal nerve fiber layer thickness is useful for the assessment of diabetic retinopathy severity. *Diabet Epidemiol Manag* 2022;7:100075. doi: 10.1016/j.deman.2022.100075.
33. Pires I, Santos AR, Nunes S, Lobo C. Macular Thickness Measured by Stratus Optical Coherence Tomography in Patients with Diabetes Type 2 and Mild Nonproliferative Retinopathy without Clinical Evidence of Macular Edema. *Ophthalmologica* 2013;229:181–6. doi:10.1159/000350593.
34. Satue M, Cipres M, Melchor I, Gil-Arribas L, Vilades E, Garcia-Martin E. Ability of Swept source OCT technology to detect neurodegeneration in patients with type 2 diabetes mellitus without diabetic retinopathy. *Jpn J Ophthalmol* 2020;64:367–77. doi: 10.1007/s10384-020-00729-0.
35. Aitchison RT, Kennedy GJ, Shu X, Mansfield DC, Kir R, Hui J, et al. Measuring the foveal avascular zone in diabetes: A study using optical coherence tomography angiography. *J Diabetes Investig* 2022;13:668–76. doi: 10.1111/jdi.13712.
36. Kim M, Choi SY, Park YH. Quantitative analysis of retinal and choroidal microvascular changes in patients with diabetes. *Sci Rep* 2018;8:12146. doi: 10.1038/s41598-018-30699-w.
37. Rosen RB, Andrade Romo JS, Krawitz BD, Mo S, Fawzi AA, Linderman RE, et al. Earliest evidence of preclinical diabetic retinopathy revealed using optical coherence tomography angiography perfused capillary density. *Am J Ophthalmol* 2019;203:103–15. doi: 10.1016/j.ajo.2019.01.012.
38. Sawada O, Ichiyama Y, Obata S, Ito Y, Kakinoki M, Sawada T, et al. Comparison between wide-angle OCT angiography and ultra-wide field fluorescein angiography for detecting non-perfusion areas and retinal neovascularization in eyes with diabetic retinopathy. *Graefes Arch Clin Exp Ophthalmol* 2018;256:1275–80. doi: 10.1007/s00417-018-3992-y.
39. Kinuthia UM, Wolf A, Langmann T. Microglia and inflammatory responses in diabetic retinopathy. *Front Immunol* 2020;11. doi: 10.3389/fimmu.2020.564077.
40. Olver JM. Functional anatomy of the choroidal circulation: Methyl methacrylate casting of human choroid. *Eye* 1990;4:262–72. doi: 10.1038/eye.1990.38.